



# Paramedic Resource Manual

## RESPIRATORY SYSTEM SECTION ONE

2014 Update by  
Ontario Base Hospital Group Education Subcommittee

# RESPIRATORY SYSTEM: OBJECTIVES

The objectives indicate what you should know, understand and be prepared to explain upon completion of this module. The self assessment questions and answers will enable you to judge your understanding of the material.

Upon completion of this module, the student should be able to:

1. identify and locate, relative to other anatomic structures, the components of the upper and lower respiratory tracts.
2. describe the function of the components of the upper and lower respiratory tracts.
3. describe the mechanics of inspiration and expiration, in association with the respiratory pressures in each phase.
4. state normal pulmonary volumes and capacities in the adult patient.
5. define compliance.
6. briefly explain ventilation/perfusion ratio.
7. describe the influence of the central nervous system on respiration.
8. briefly describe the pathophysiology and clinical presentation of:
  - o Asthma
  - o COPD
  - o Emphysema
  - o Bronchitis.
9. relate the objectives to clinical situations you may encounter in the field, utilizing the EMCA level skills of patient assessment and airway management.

If you have studied this subject previously, you may test your ability using the self assessment questions. if you are able to obtain 90% or greater, you may choose not to do the unit and merely review the sections, or parts of sections, where weakness may exist. if you obtain less than 90%, it is recommended that the module be done in its entirety, stressing areas where more review is needed.

## ADVANCED LIFE SUPPORT PRECOURSE RESPIRATORY SYSTEM

Adequate patient care demands that each paramedic be able to assess a patient's airway and ventilation and manage any problems that exist. This assessment cannot be done well without a knowledge of the basic anatomy and function of the respiratory system.

The structure of the respiratory tract is closely correlated with its function. The architecture consists of a series of air passages that convey air to the lungs. As air passes through the upper conducting channels, it is filtered, warmed and humidified.

### UPPER RESPIRATORY TRACT

The sequence of organs that comprise the upper conducting pathway are:

- o Nasal cavity and sinuses
- o Pharynx
- o Larynx
- o Trachea.

### NASAL CAVITY

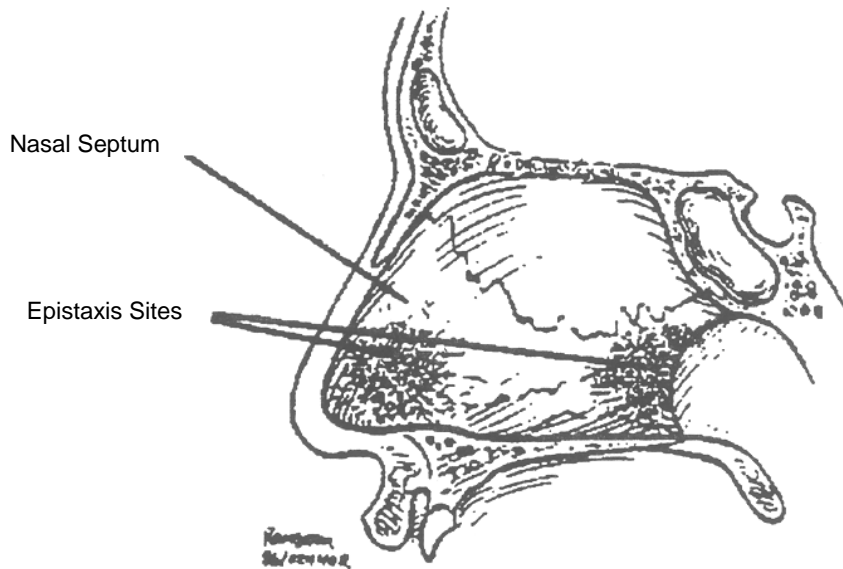
Reasons to know the nose:

- o Placement of nasopharyngeal airways
- o Placement of nasotracheal tubes
- o Nose bleeds (epistaxis)
- o Fractured nose.

The nasal cavities are separated from each other by the **nasal septum**. They open in front at the nostrils (anterior nares) and posteriorly into the nasopharynx through the posterior nares (choanae). The septum is composed of cartilage anteriorly and bone posteriorly. It is covered by a very vascular mucous membrane.

Most nose bleeds in younger people originate at the anterior nasal septum, while those in older people are often from the posterior nasal structures.

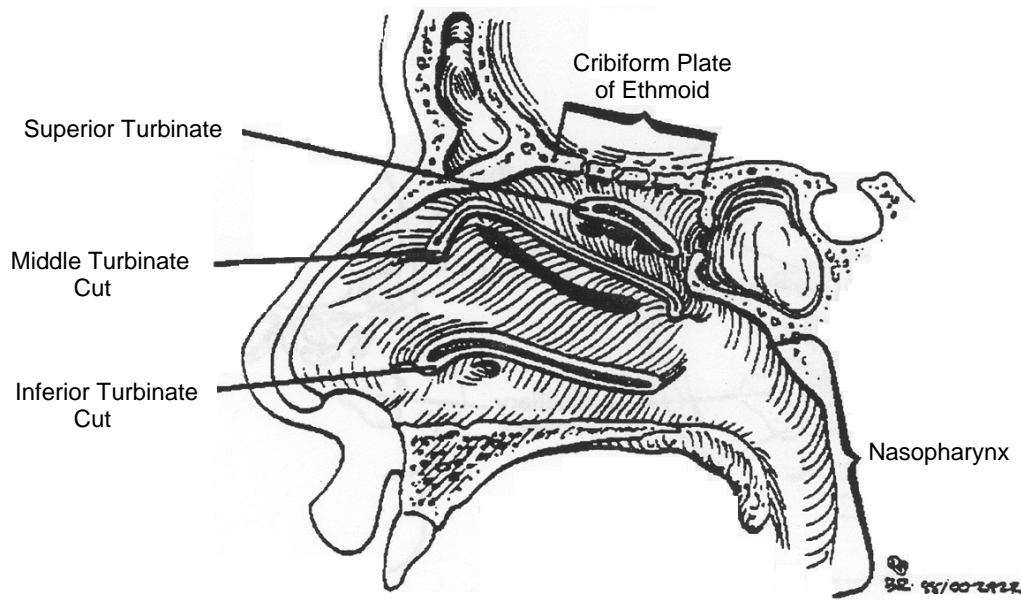
**FIGURE 1: SITES OF ANTERIOR AND POSTERIOR NOSEBLEEDS**



On the lateral wall of each nasal cavity are three scroll-like elevations of bone covered with mucous membrane. These are the superior, middle and inferior turbinates.

Displacement of the turbinates is responsible for the unpleasant "crunching" noise often encountered in placement of a nasotracheal tube. Should turbinate laceration occur, significant bleeding may result.

**FIGURE 2: ANATOMY OF THE NOSE**



The cribriform plate is the thin layer of bone that separates the brain from the nasal cavity. Its multiple perforations allow entry of the olfactory nerve fibres into the nose. With facial or head trauma the cribriform plate may fracture, allowing leakage of cerebrospinal fluid into the nose (CSF rhinorrhea). Attempting to pass any tube through the nose in such a patient may result in the tube passing through the fracture into the cranium with disastrous consequences.

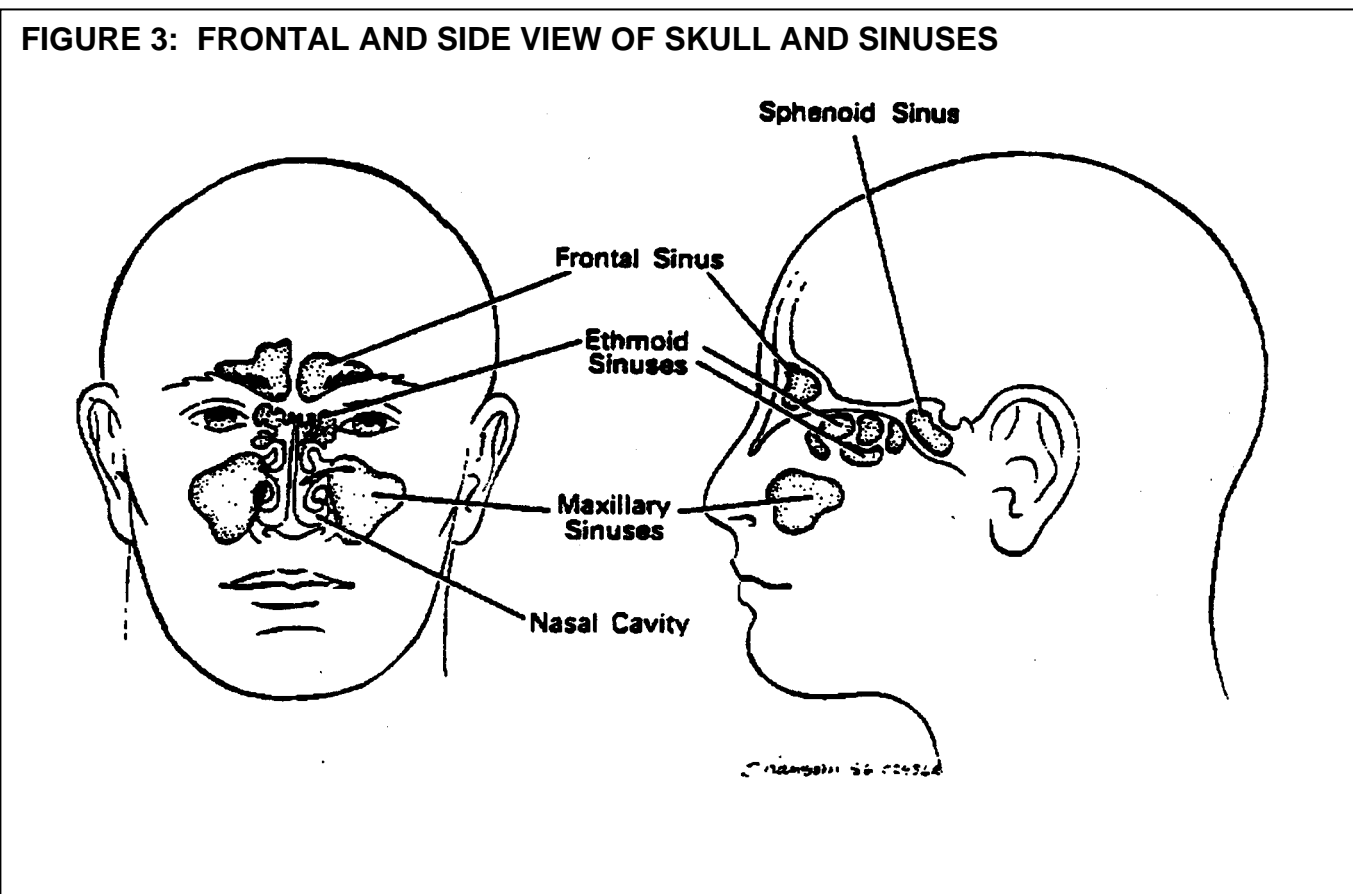
## SINUSES

### Sinus Highlights

- o Sinus infections can lead to headache.
- o Ethmoid sinuses occasionally rupture with pressure changes.
- o Sinusitis may lead to brain abscess.
- o Air-fluid level in the sphenoid sinus may indicate a basal skull fracture.

The nasal sinuses are the **ethmoidal**, **frontal**, **maxillary** and **sphenoid**. Each sinus is a mucous membrane lined, air-filled cavity within the bony architecture of the skull which drains into the nasal cavity.

Obstruction of drainage from a sinus can lead to pain and infection (sinusitis). Occasionally an infected sinus will erode through its bony box into the cranium leading to a brain abscess. With rapid depressurization, **e.g.** a rapid surfacing from depth, an ethmoidal sinus may rupture leading to facial subcutaneous emphysema.



Often basal skull fractures extend into the sphenoidal sinuses, resulting in bleeding. The presence of an air fluid level in the sphenoid sinus following head trauma may be the only radiographic sign of the fracture.

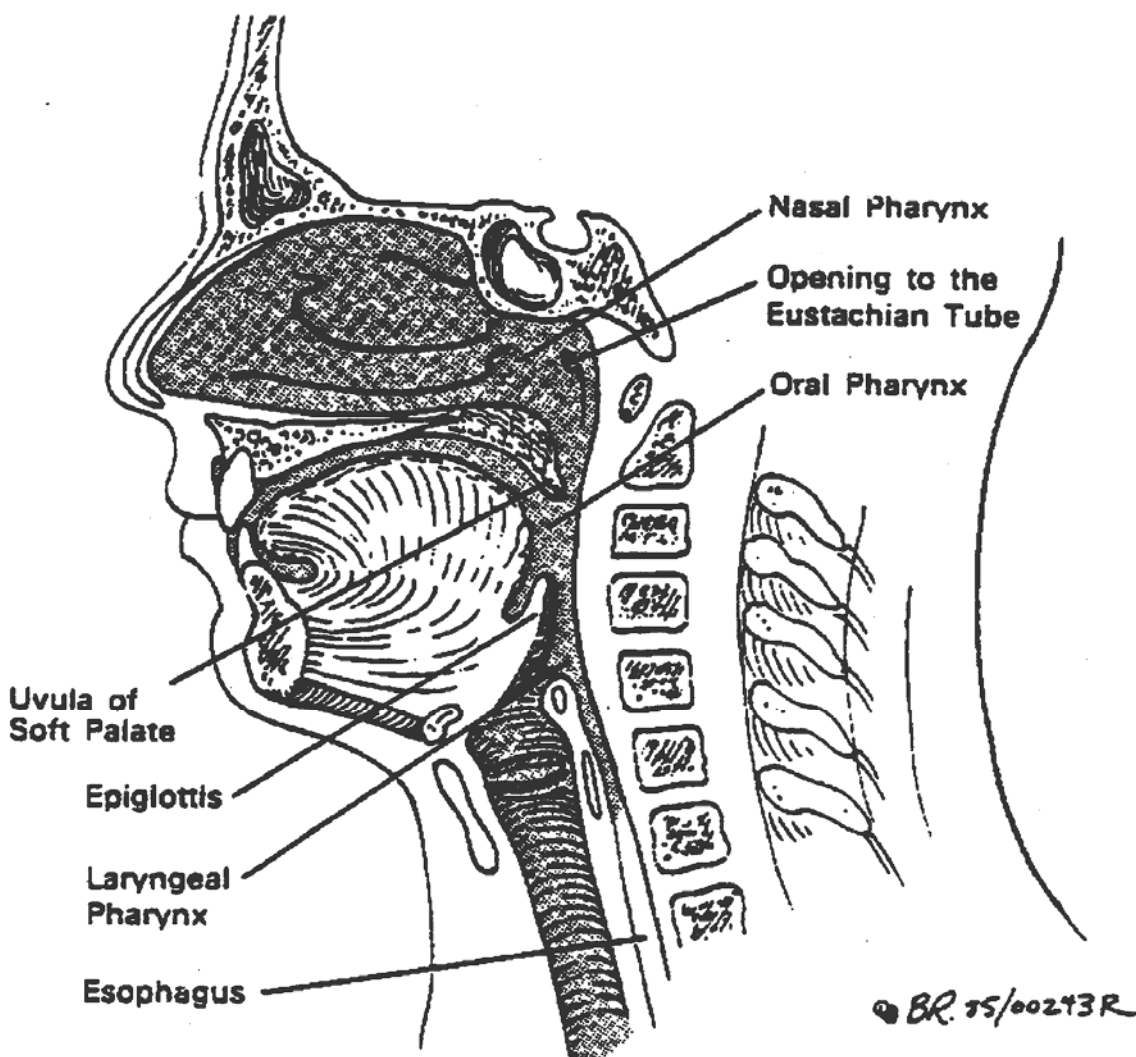
## THE PHARYNX

### Pharyngeal Facts

- o Foreign bodies may lodge in the pharynx (especially laryngopharynx).
- o Abscesses in this area may lead to airway obstruction.
- o Swelling secondary to allergic reactions or burns may lead to airway obstruction

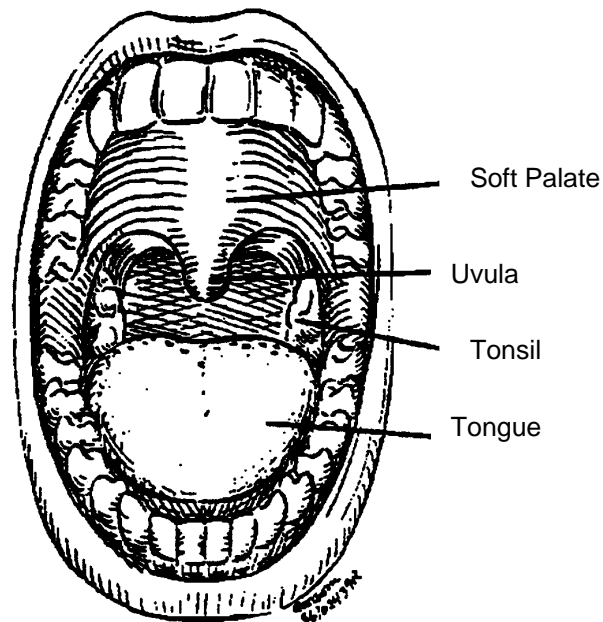
The pharynx is the space extending from the base of the skull to the larynx. The part behind the nose is the nasal pharynx (nasopharynx), behind the mouth is the oral pharynx (oropharynx) and behind the larynx is, you guessed it, the laryngeal pharynx (laryngopharynx).

**FIGURE 4: LATERAL ASPECT OF THE PHARYNX**



When looking through the mouth into the oral pharynx one can see the soft palate, uvula and tonsils.

**FIGURE 5: VIEWTHROUGH OPEN MOUTH**



## THE LARYNX

Don't be lax about the larynx

- Airway obstruction, often due to foreign bodies at this level.
- Any mucosal swelling of larynx can cause airway obstruction.
- The larynx is very vulnerable to direct trauma.
- Trauma to the larynx is often associated with cervical spine injury.
- Emergency airway can be obtained by inserting cannulae through the cricothyroid membrane.

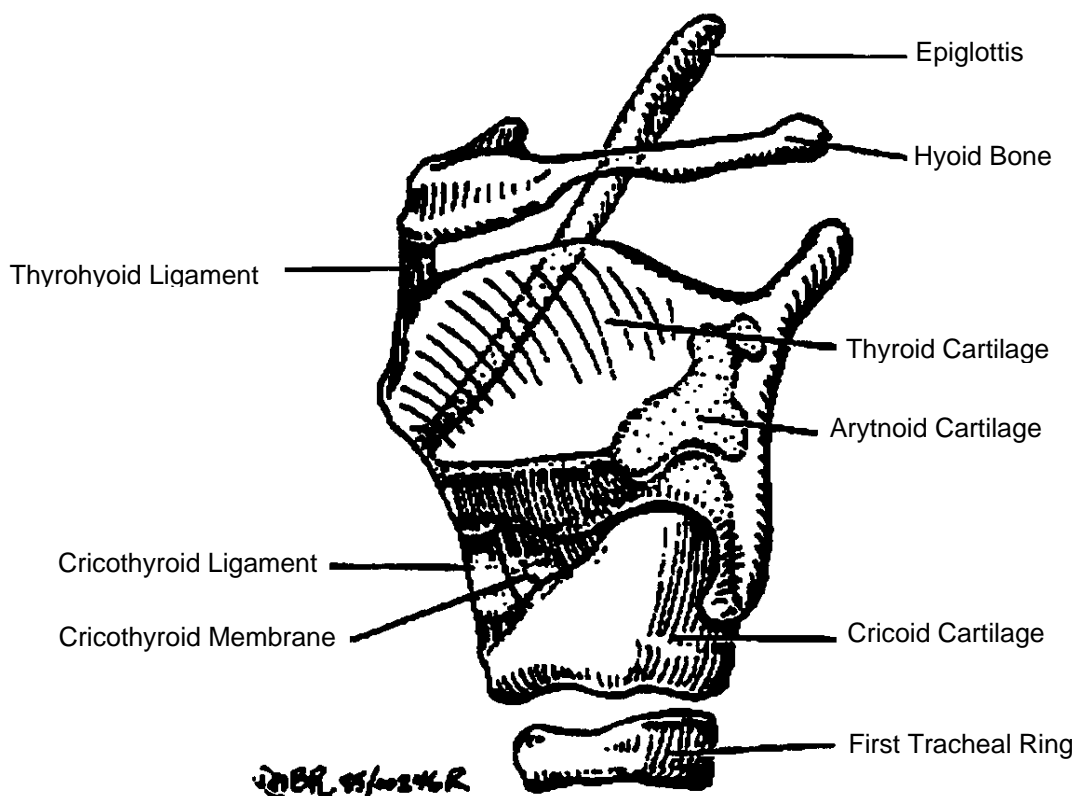
Disruption of normal laryngeal function or structure may lead to airway compromise. Common problems are:

1. Laryngeal foreign bodies
2. Epiglottitis
3. Edema, secondary to either burns, chemical inflammation, or allergic reactions
4. Trauma, with secondary bleeding and swelling, **e.g.** inexperienced attempts at intubation
5. Trauma, with gross disruption of laryngeal structures with associated major airway obstruction. Often air will leak out of the larynx leading to subcutaneous emphysema.

The larynx extends from the hyoid bone to the lower border of the cricoid cartilage. It lies anterior to the 3rd to the 6th cervical vertebrae (hence the common association of laryngeal and cervical fractures). The larynx is composed of cartilages united by ligaments and moved by muscles. The whole structure is lined with mucous membrane.

The four major laryngeal cartilages are the epiglottis, thyroid, arytenoids, and cricoid.

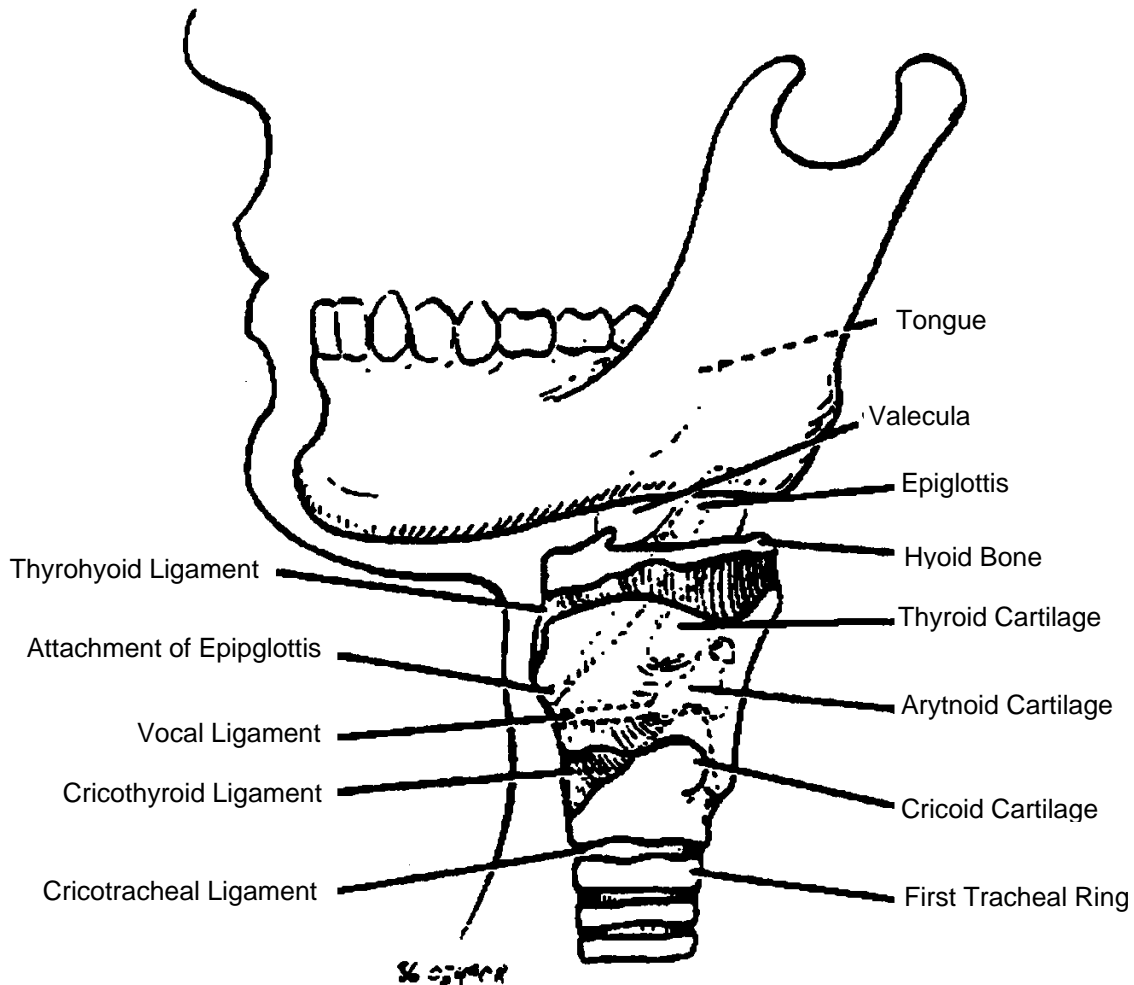
**FIGURE 6: CARTILAGES OF THE LARYNX**





Take a moment to palpate your own neck while referring to Figure 7 and reading the discussion which follows.

**FIGURE 7: LATERAL ASPECT OF THE LARYNX**



Immediately below your chin you will find a mobile bone of 4-5 mm in width which moves superiorly when you swallow. This is the hyoid bone. It resembles a horseshoe in shape.

Below the hyoid bone one next encounters the thyroid cartilage. It is easily identified by its most prominent protuberance, the "Adam's Apple". The thyroid cartilage acts as both an attachment for and protection to the vocal cords. The ligament that connects the hyoid bone and thyroid cartilage is thyrohyoid ligament.

Immediately below the thyroid cartilage one can palpate a gap and below this which is the cricoid cartilage. The ligament between the thyroid and cricoid cartilages is the cricothyroid ligament (and membrane).

You must be able to reliably locate the space between the thyroid and cricoid cartilages. A cannula may be placed through this membrane to allow oxygenation and ventilation of the patient (cricothyroidotomy).

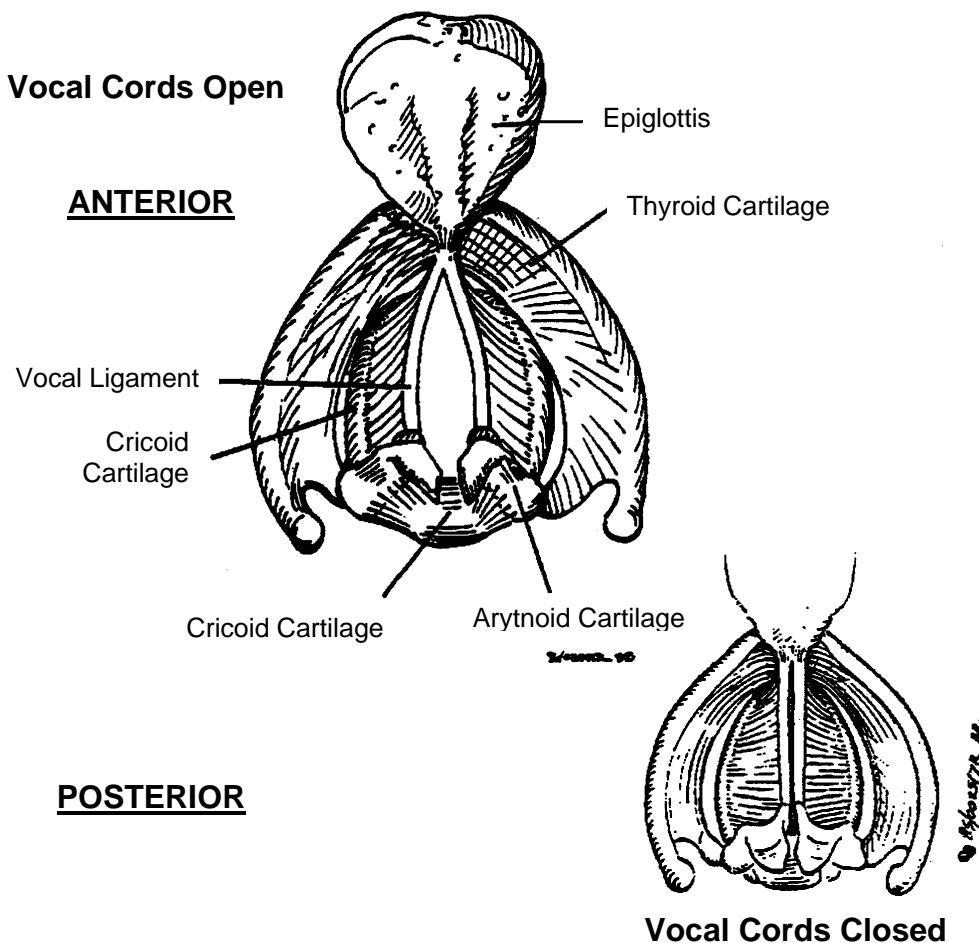
The epiglottis is found behind the hyoid. It cannot be palpated through the skin.

The epiglottis is a semirigid cartilagenous structure found immediately posterior to the base of the tongue. It is directly behind the hyoid bone. (During oral-tracheal intubation, one must lift the epiglottis anteriorly in order to visualize the vocal cords).

The epiglottis is 2-3 mm thick and has a curved shape when viewed from above. It is normally pale pink in colour. During swallowing, the epiglottis slides superiorly and posteriorly to cover the top of the larynx. This prevents aspiration of foreign material into the larynx. (The coughing and sputtering we have all experienced when something "goes down the wrong way" illustrates what happens if the epiglottis doesn't prevent this). Any swelling of the epiglottis can lead to significant airway obstruction.

The vocal cords (ligaments) stretch from the back of the thyroid cartilage to the arytenoid cartilages. They are mobile structures capable of opening and closing.

**FIGURE 8: THE VOICE APPARATUS  
(INTERIOR OF LARYNX, SUPERIOR ASPECT)**



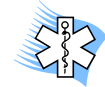The vocal cords are opened by muscles controlled by the recurrent laryngeal nerves. Damage to one recurrent laryngeal nerve results in ipsilateral cord paralysis. This results in a hoarse voice. Damage to both nerves leads to marked airway obstruction.

## TRACHEA

Below the cricoid cartilage one may palpate the first few tracheal rings. The trachea extends from the cricoid cartilage, opposite the sixth cervical vertebra, to the fifth thoracic vertebra.

The trachea bifurcates into the right and left mainstem bronchi. The area of bifurcation is called the carina.

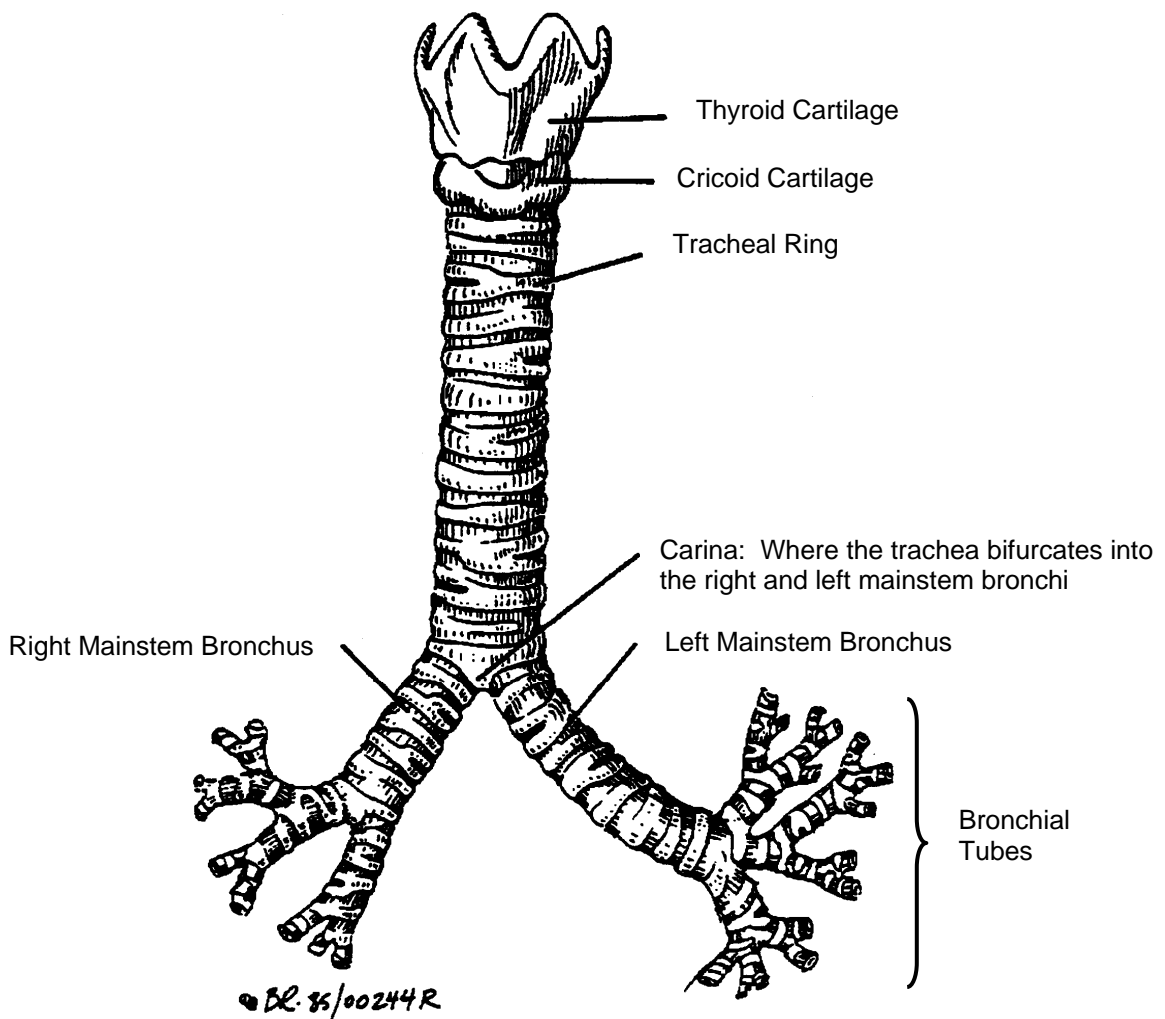
The trachea is about 10 cm long and lies immediately anterior to the esophagus.



### Clinical vignette

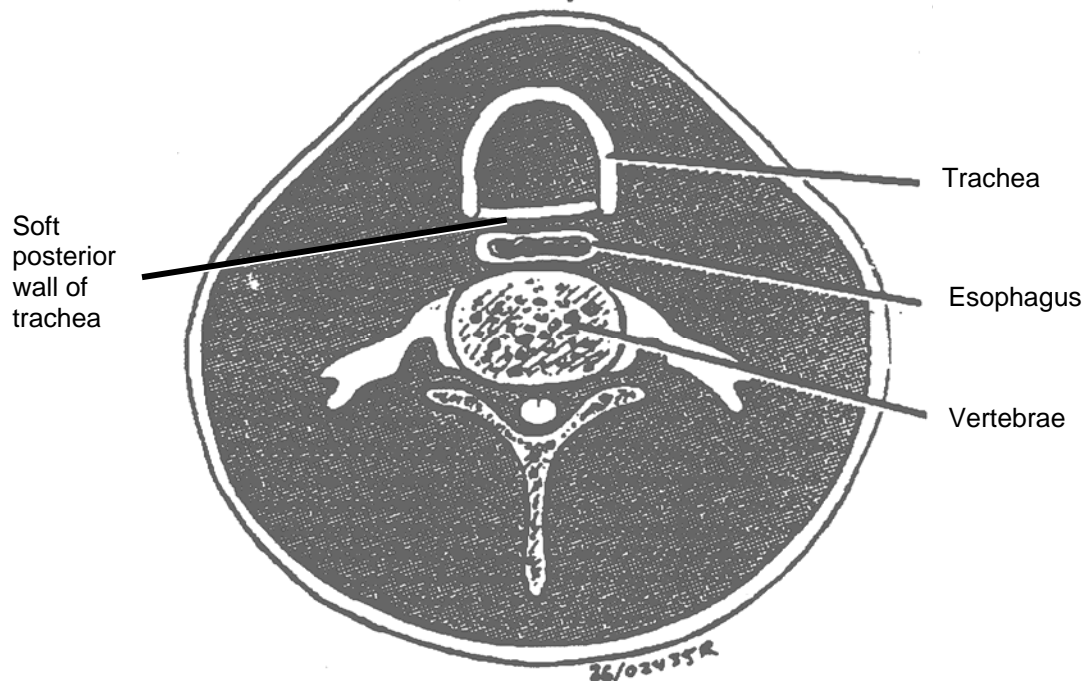
Trachea is only 10 cm long, therefore beware you don't insert the endotracheal tube too deeply.

**FIGURE 9: THE TRACHEA**



Each of the 16-20 tracheal cartilages is horseshoe shaped with the opening facing posteriorly.

**FIGURE 10: RELATIONSHIP OF TRACHEA AND ESOPHAGUS**



The lack of cartilagenous continuity of the tracheal rings is important for food to move through the esophagus, **i.e.** the posterior wall of the trachea can bulge anteriorly allowing most objects to pass.



### **Clinical vignette**

Because the rings of the trachea are semi-lunar and do not completely encircle the trachea, the posterior wall is soft and compressible. A large foreign body lodged in the esophagus can obstruct the trachea and drastically restrict air movement. This is especially true in infants and smaller children. Glucagon, given IV and in a higher dose than that which is used to raise blood sugar levels, will relax the esophagus and may relieve an obstruction.

The trachea is lined by ciliated columnar epithelium. It is these cilia that sweep foreign matter including bacteria from the trachea.

In summary, the upper respiratory tract consists of the nose, larynx, pharynx and trachea. It serves to conduct air to the lower respiratory tract and warms, moistens and filters the air during passage.

## LOWER RESPIRATORY TRACT

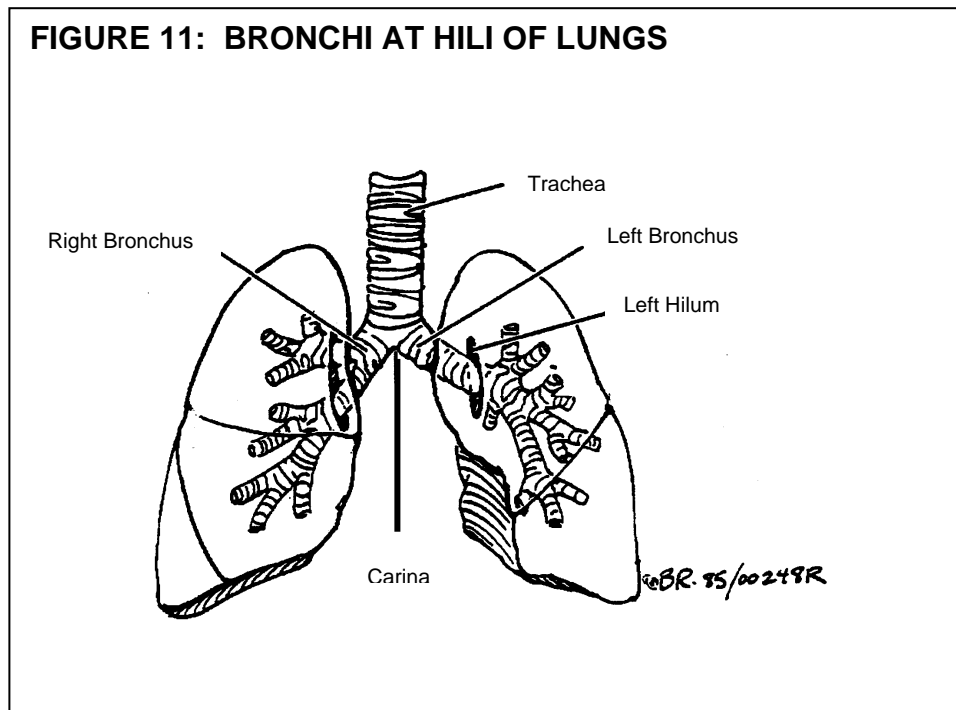
When air has passed through the structures of the upper respiratory tract, it enters the **lower respiratory tract** which consists, in a descending order, of:

1. Right and left mainstem bronchi
2. Secondary bronchi
3. Tertiary bronchi
4. Bronchioles
5. Terminal bronchioles
6. Respiratory bronchioles
7. Alveolar ducts
8. Alveolar sacs
9. Alveoli

There are also associated structures, including the **pleura, pleural cavity, bony thorax** and muscles of respiration.

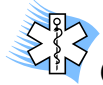### BRONCHI

The trachea ends by dividing into the right and left mainstem bronchi (singular= bronchus). These are also referred to as the primary bronchi. Each bronchus enters the lung through the **hilum**, as shown in Figure 11. The mainstem bronchi are similar in structure to the trachea, in that they have the characteristic rings of cartilage and their lining is ciliated epithelium. However, as progressive subdivision ensues, less and less cartilage is present in their walls. The cartilage is replaced by smooth muscle.



## RIGHT BRONCHUS

The **right mainstem bronchus**, approximately five centimeters long, is shorter, more vertical in direction and of larger calibre than the left. It passes to the root or hilum of the corresponding lung (Figure 11).



### Clinical vignette

Because the right mainstem bronchus is almost in a direct line with the trachea, most foreign bodies that pass the carina end up in the right mainstem bronchus. This is also true for endotracheal tubes that have been inserted too far.

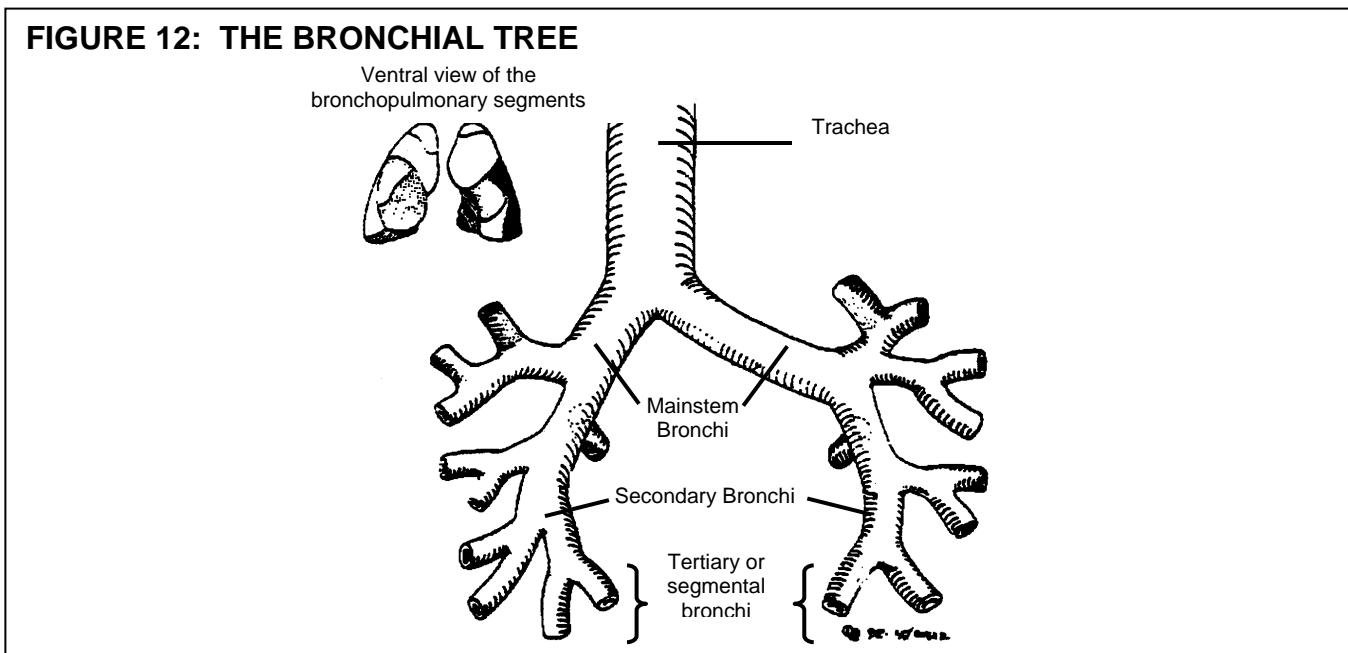
## LEFT BRONCHUS

The **left bronchus** is a little longer than five centimeters and leaves the tracheal bifurcation at a greater angle (about  $45^{\circ}$ ) than does the right (about  $25^{\circ}$ ) (Figure 12).

## BRONCHIAL TREE

Each bronchus, upon entering the lung, will divide into **secondary** bronchi (Figure 12), which in turn will sub-divide into smaller units, the **tertiary** bronchi. Each tertiary bronchus leads to a **bronchopulmonary segment**. There are ten such segments in the right lung and nine in the left.

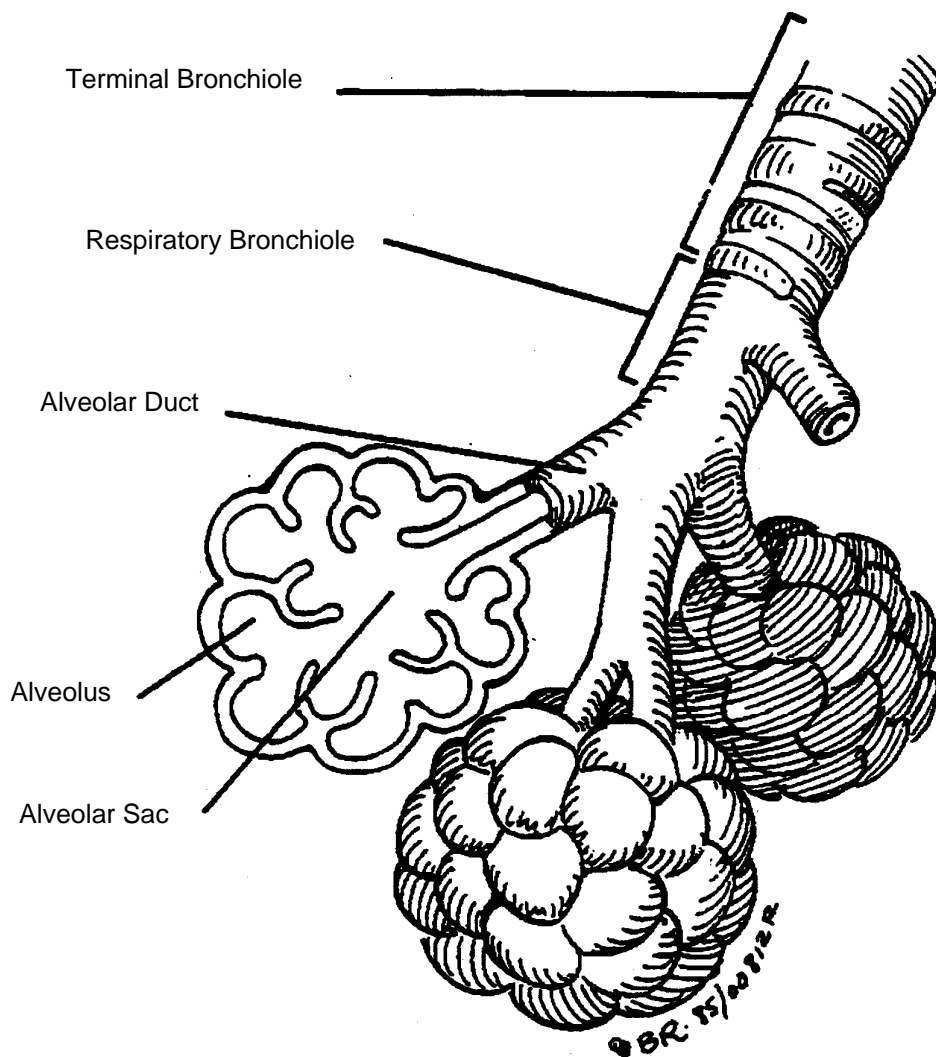
The division of the bronchi continues, in tree-like fashion and indeed, the resultant structure is referred to as the **bronchial tree**. The fine bronchial tubes at the periphery of the "tree" are the bronchioles.



## BRONCHIOLES

The terminal branches of the bronchioles are the **respiratory bronchioles** (Figure 13), so called because they are the first sites where gas exchange takes place. Each respiratory bronchiole gives off several branches called **alveolar ducts**. The alveoli open directly into the duct or pass through an intervening structure, the **alveolar sac**.

**FIGURE 13: TERMINAL DIVISION OF THE BRONCHIOLES**

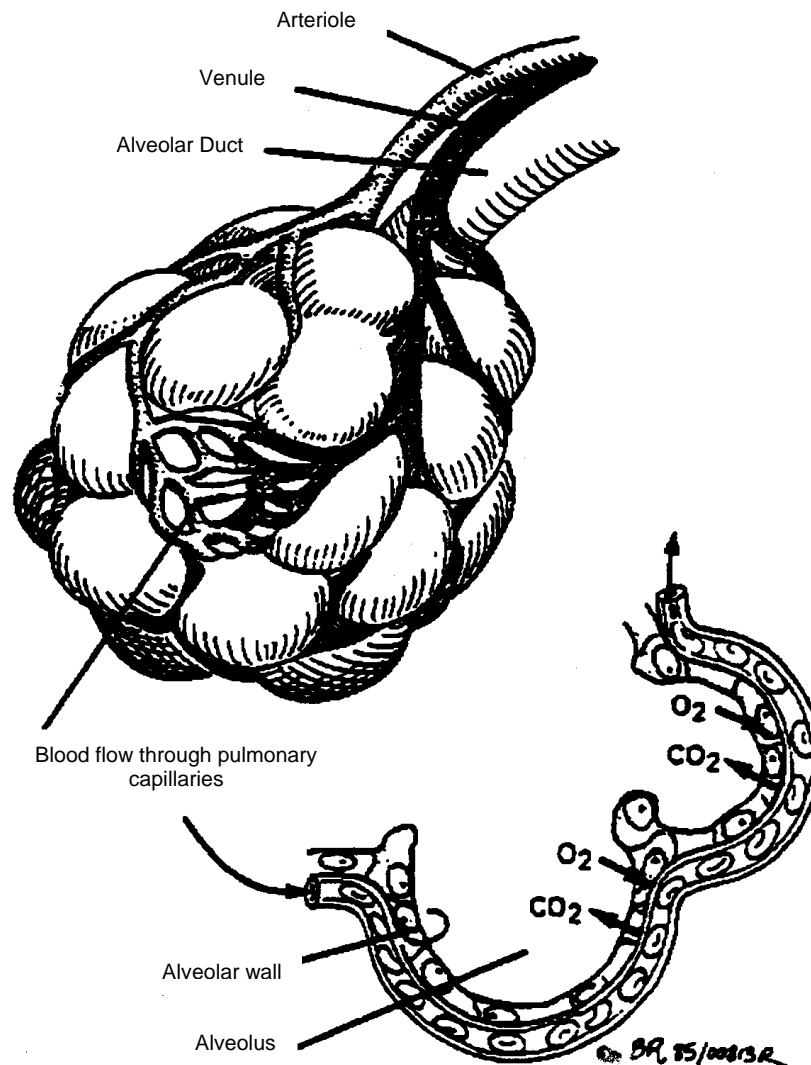


## ALVEOLUS

The structure separating the air in the alveoli from the blood in the capillaries is called the **respiratory membrane**. It consists of a thin film of surfactant, a layer of alveolar epithelial cells, a tiny interstitial space, the capillary basement membrane and finally the endothelial cell forming the capillary cell wall.

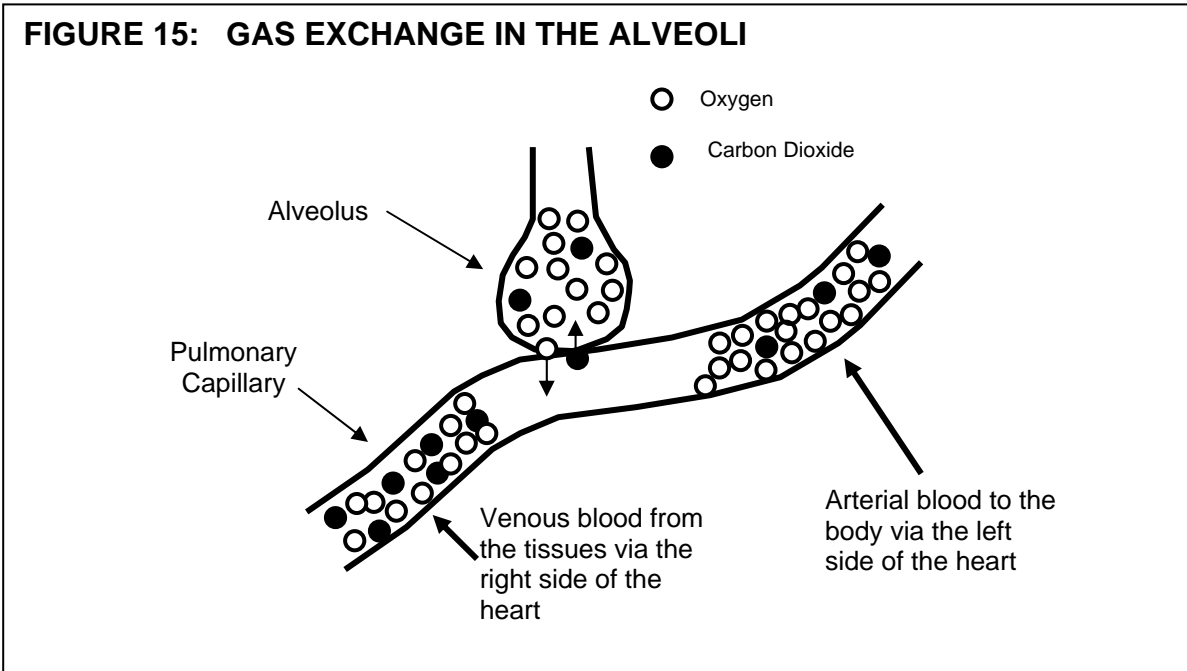
The total alveolar surface area is approximately 70 m<sup>2</sup>. Carefully arranged, you could park 20 cars in a space this size. It is through the respiratory membrane that gas exchange occurs. Anything that thickens this membrane will impair gas exchange, **e.g.** interstitial edema often associated with congestive heart failure and interstitial pneumonia.

**FIGURE 14: STRUCTURE OF ALVEOLI AND SURROUNDING CAPILLARY NETWORK**



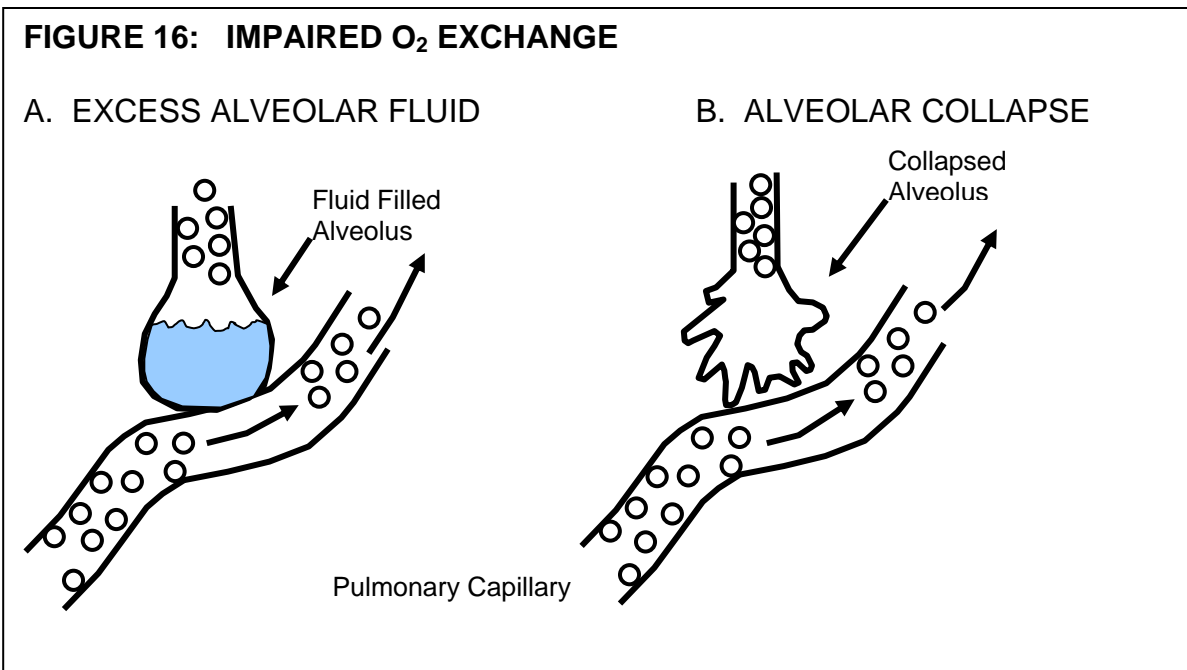


Blood returning to the lungs from the tissues has reduced levels of  $O_2$  and increased levels of  $CO_2$  as a consequence of cellular respiration. During passage around the alveolus, excess  $CO_2$  is unloaded and  $O_2$  stores replenished. Oxygen is taken up from the alveolus while carbon dioxide is released into the alveolus (Figure 15).



Oxygen exchange can be markedly impaired by a number of alveolar processes, such as:

- excess alveolar fluid as in pulmonary edema
- alveolar collapse as in atelectasis or a pneumothorax resulting in shunting.

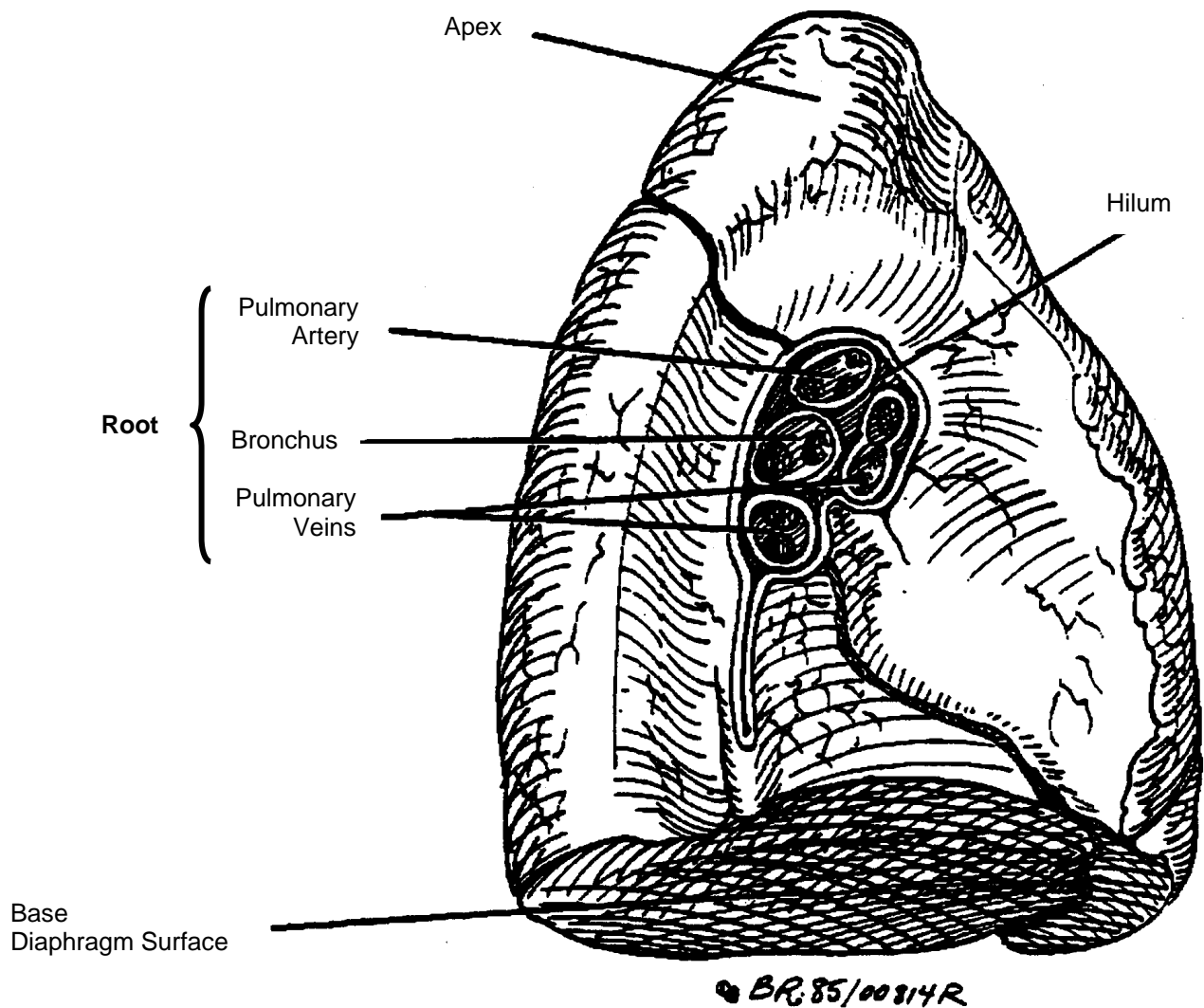


## LUNGS

The **lungs** are cone-shaped organs, which occupy most of the thorax, excepting the **mediastinum**, which separates them and contains the heart and major vessels. The base of each lung lies in contact with the upper surface of the **diaphragm** while the **apex** extends about 2 cm above the level of the clavicle (collar bone).

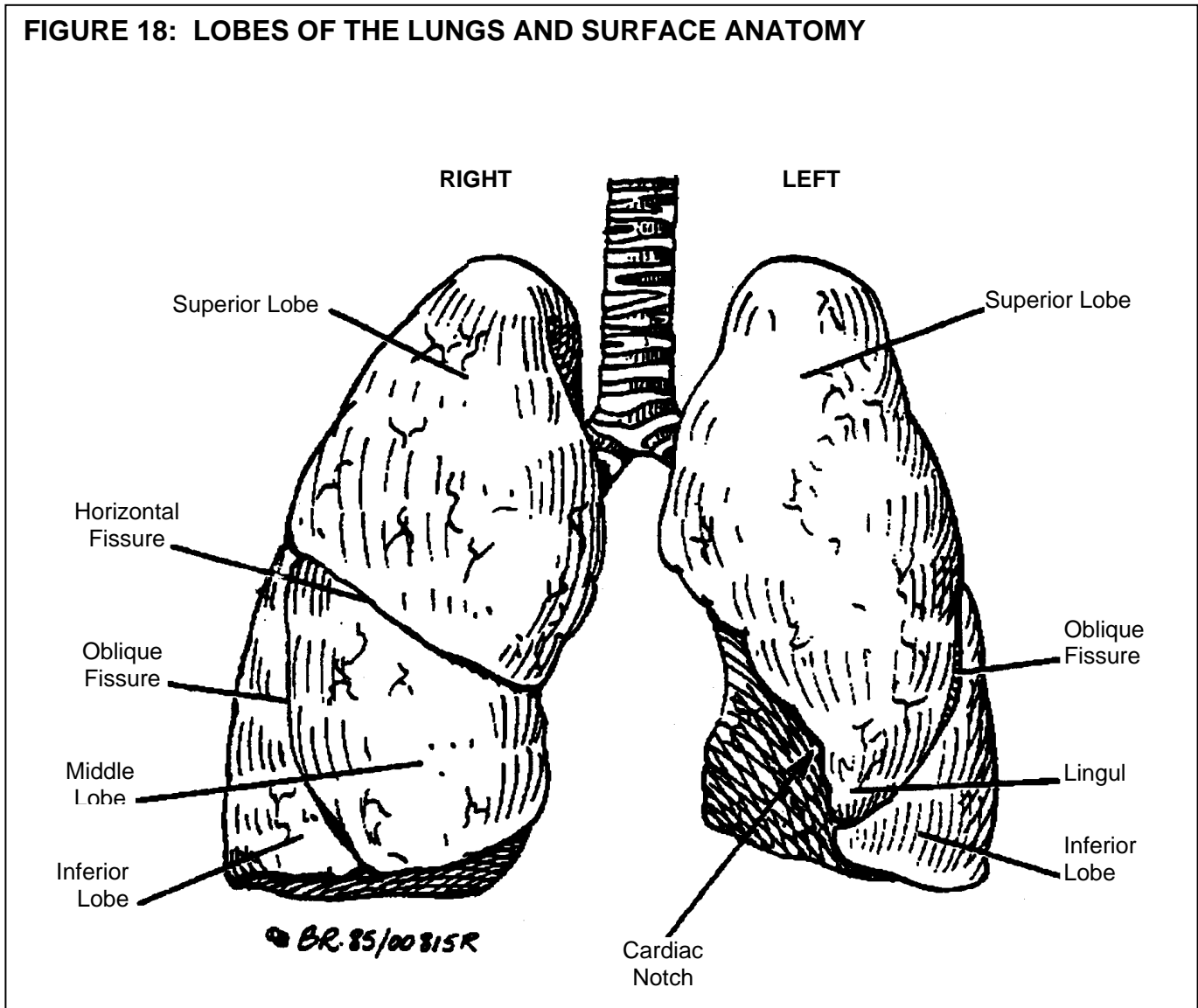
On the medial surface of each lung is a slit, the **hilum**, where structures enter and leave the lung. The **bronchi**, **blood vessels**, **nerves** and **lymphatic vessels** that enter and leave the lung through the hilum, form the root of the lung which constitutes its only firm attachment.

**FIGURE 17: MEDIAL ASPECT OF THE LEFT LUNG**



The right lung, which is larger than the left, is divided by **horizontal** and **oblique fissures** into **superior, middle** and **inferior lobes** (Figure 18). The smaller and narrower left lung is divided by an oblique fissure into superior and inferior lobes. The **lingula**, a small tongue of lung tissue between the oblique fissure and the cardiac notch, is a part of the upper lobe (Figure 18).

**FIGURE 18: LOBES OF THE LUNGS AND SURFACE ANATOMY**

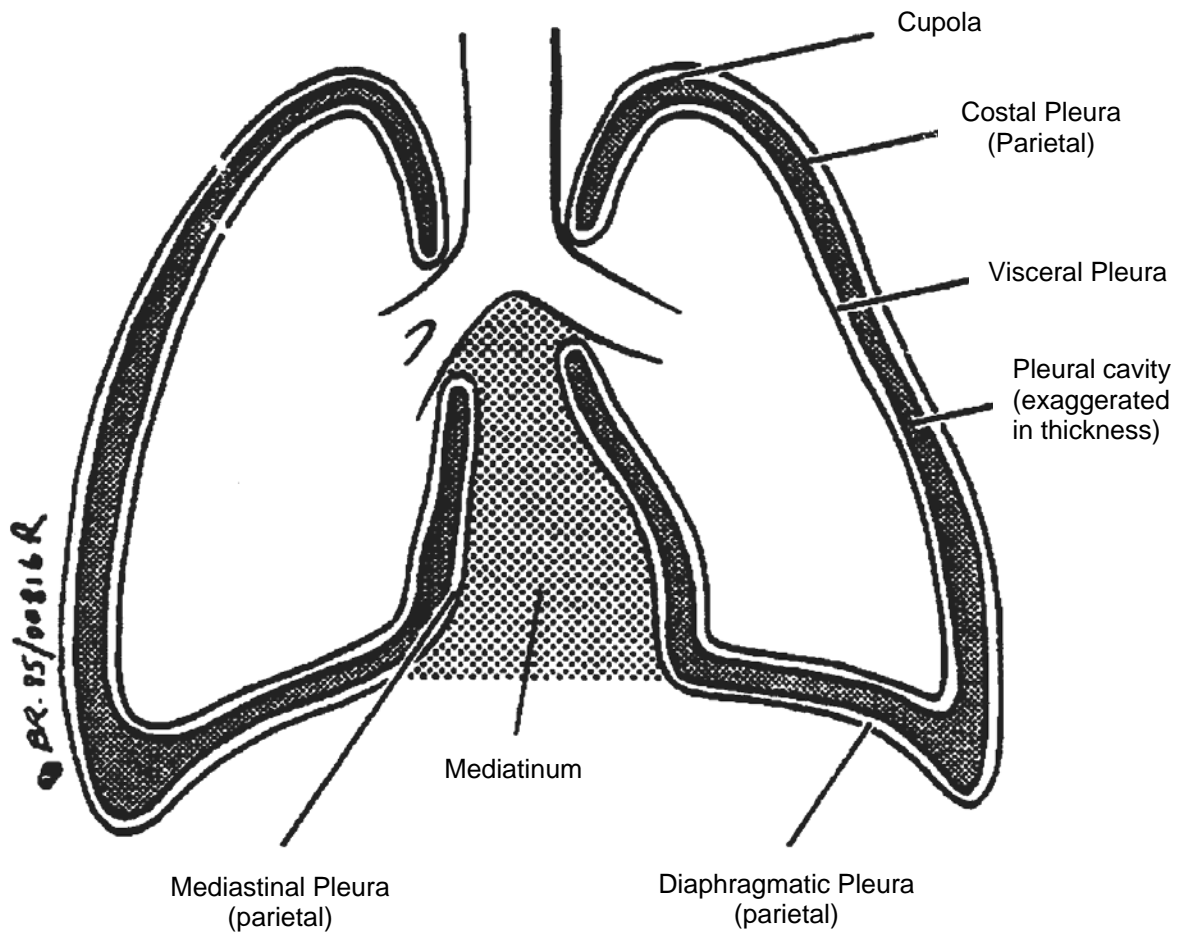


Location of these lobes assumes clinical importance when reporting findings during chest auscultation. One must also understand the normal sounds you **expect** to find in each area. Auscultate from apices to bases. For confirmation of endotracheal tube (ETT) placement: Auscultate just below the xyphoid (to rule out breath sounds in the stomach from a misplaced ETT in the esophagus), then over the right chest, high mid-axillary line, then over the left chest, high mid-axillary line.

## PLEURAE

The **pleurae** are two serous sacs enclosing the lungs. The pleura that adheres to the surface of the lung (the **visceral pleura**), is reflected from the root of the lung onto the inner surface of the chest wall, diaphragm and the lateral surface of the mediastinum, to form the **parietal pleura** (Figure 19). The parietal pleura then has **costal**, **diaphragmatic** and **mediastinal** parts.

FIGURE 19: PLEURAE



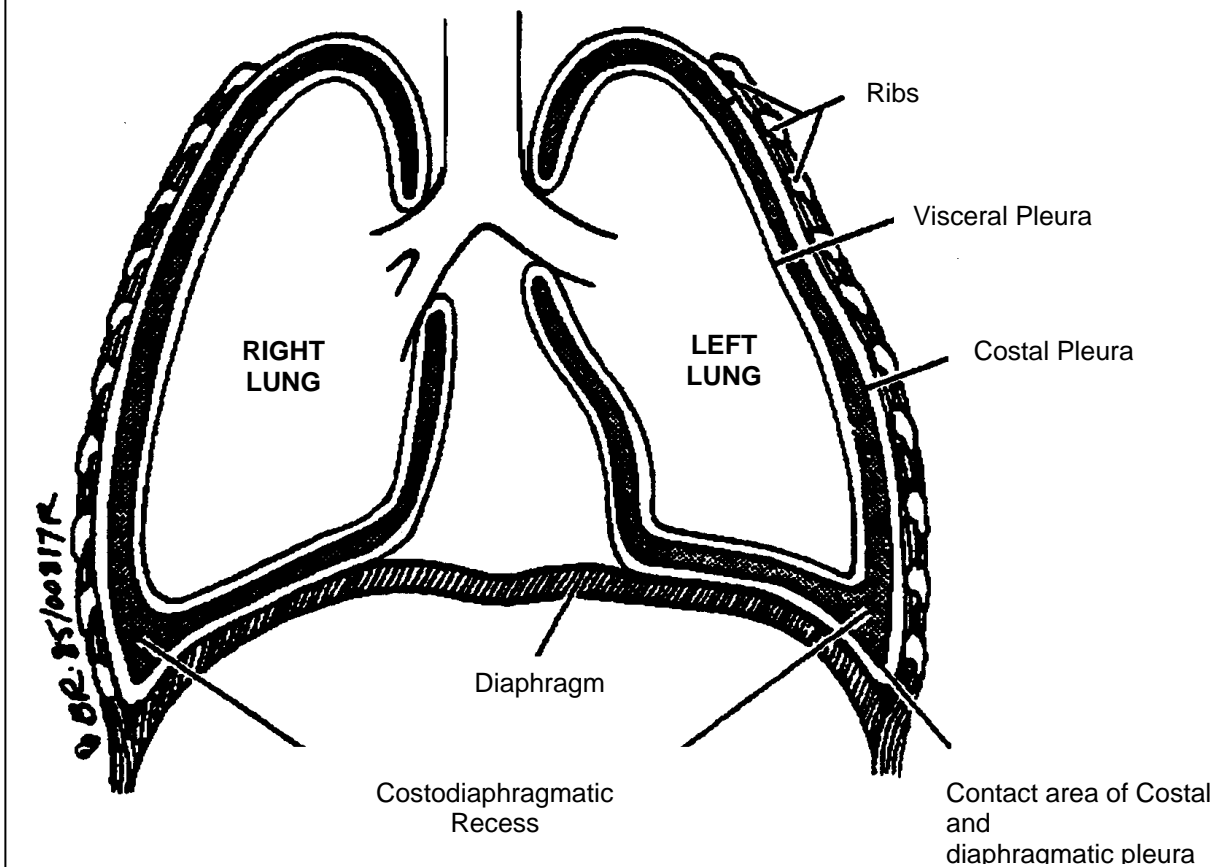
## PLEURAL CAVITY

The parietal and visceral layers of the pleurae are moist and separated by only a thin layer of serous fluid, perhaps less than 0.02 mm in thickness (Figure 19). Normally the parietal and visceral surfaces are in apposition so that the **pleural cavity** is a **potential space** rather than a real space. There is a negative intrapleural pressure within this "space" when it is intact. The adherence of the pleural layers is by a bond similar to that holding two plates of glass together. This pleural bond can be easily destroyed if air (pneumothorax) or fluid accumulates in the pleural space.

## PLEURAL RECESSES

In quiet respiration there are certain places where the lungs do not completely fill the pleural cavity. These unfilled areas of the pleural sac are known as **pleural recesses**. Two of the more obvious and important ones are the **right and left costodiaphragmatic recesses**, where the periphery of the diaphragm is close to the costal wall. Small pleural effusions will accumulate in these recesses when the patient is erect.

**FIGURE 20: COSTODIAPHRAGMATIC RECESSES**



## THORAX

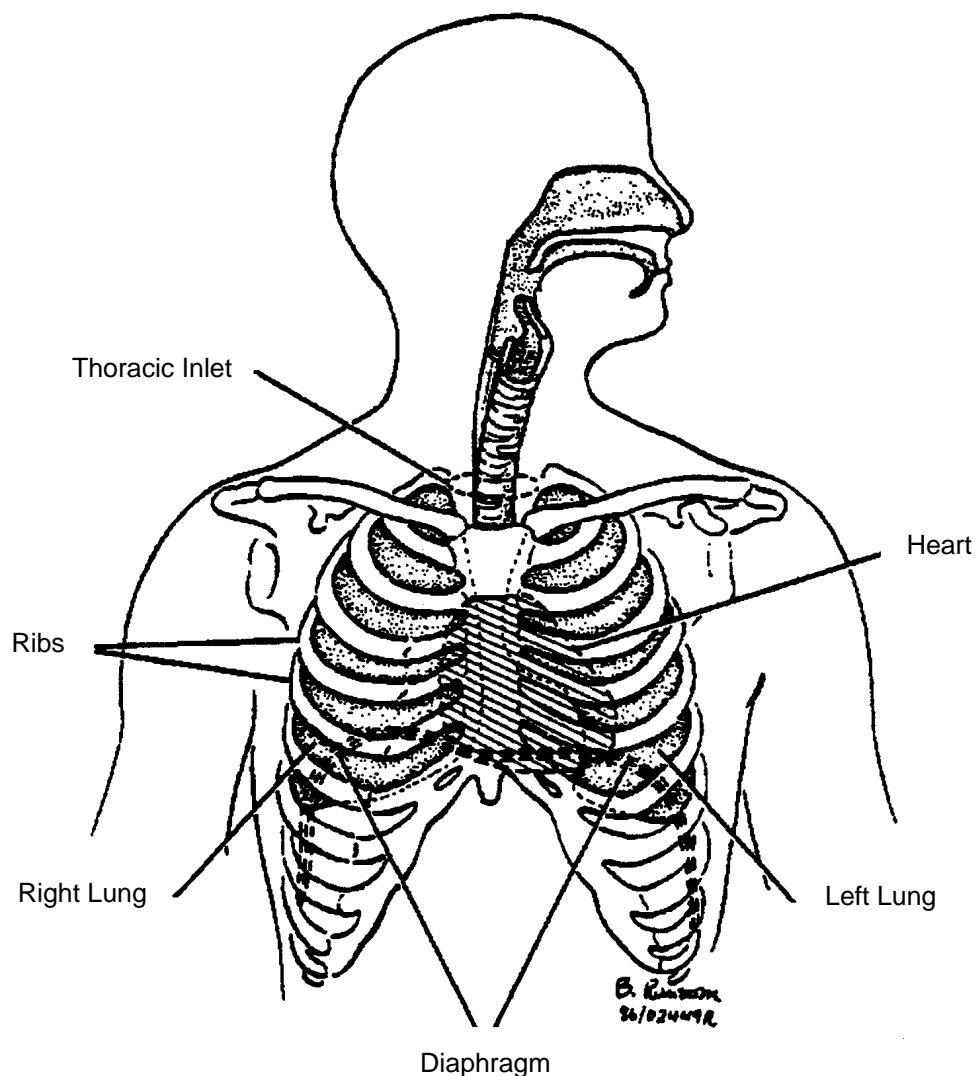
The thorax is the bony structure that forms part of an air-tight box around the lungs.

The boundaries of the thorax are:

- o Superiorly - thoracic inlet
- o Laterally - ribs
- o Anteriorly - sternum and ribs
- o Posteriorly - ribs, thoracic vertebrae (spine)
- o Inferiorly - diaphragm.

The thoracic inlet is the opening that marks the boundary between the neck and the thorax.

**FIGURE 21: ANATOMY OF THE THORACIC CAVITY**

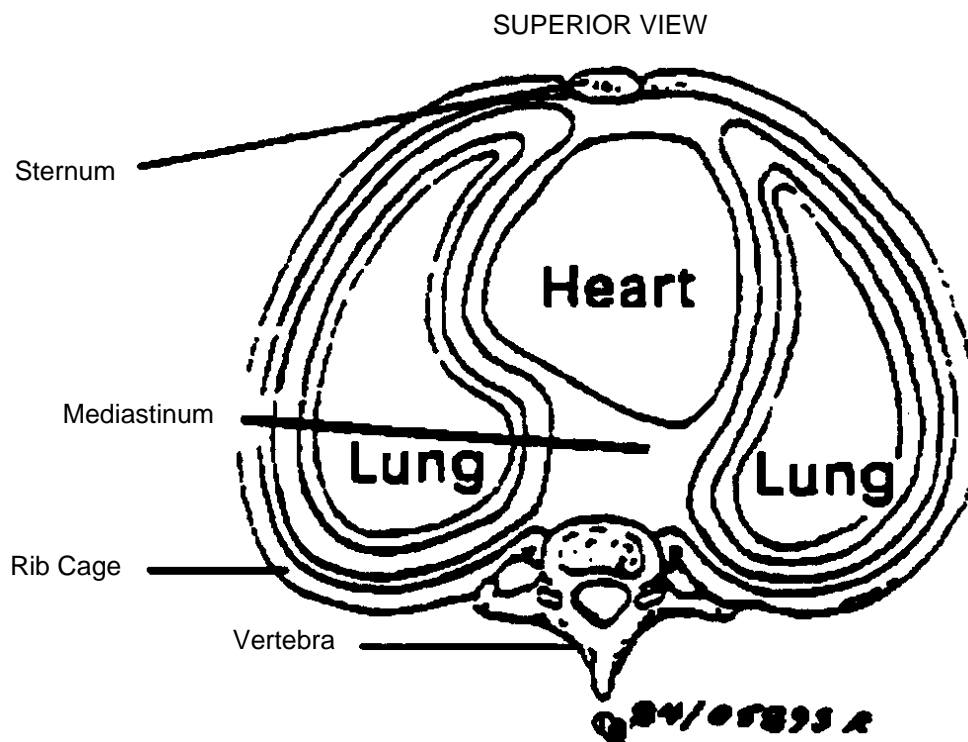


## THORACIC CAVITY

The thoracic (chest) cavity is divided, for descriptive purposes, into three main parts. The right and left pleural cavities and the mediastinum, which lies in the midline.

The pleural cavities contain the lungs and pleurae, while the mediastinum contains important midline structures, **e.g.** heart, trachea, esophagus.

**FIGURE 22: CROSS SECTIONAL VIEW OF THE THORAX**



## MECHANICS OF VENTILATION

Air, like water, flows from areas of higher pressure to areas of lower pressure. Where there is no pressure gradient, there is no flow. For inspiration to occur the alveolar pressure must be less than the atmospheric pressure at the mouth. There are only two possible means to achieve this pressure gradient:

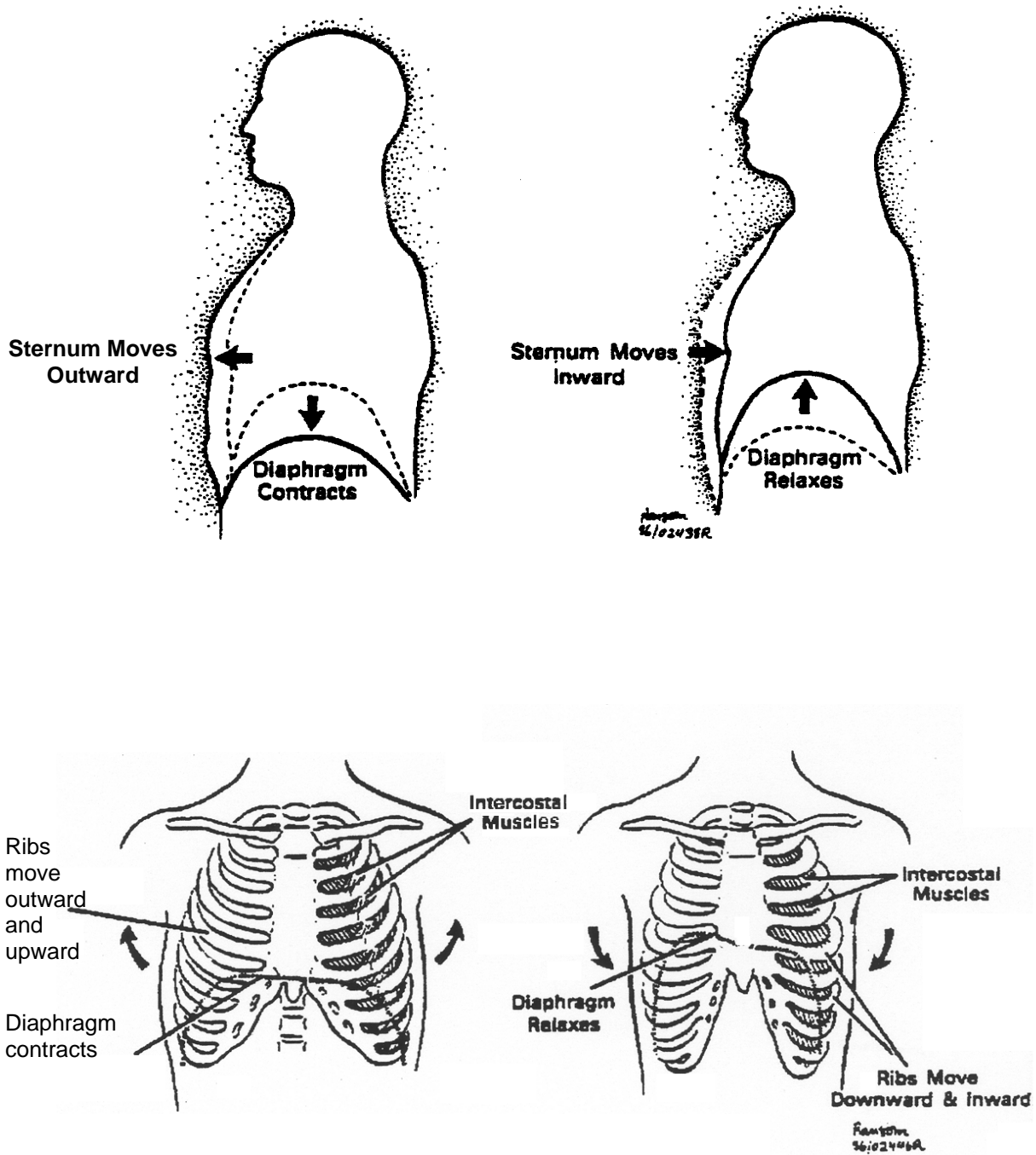
1. The alveolar pressure can be lowered below atmospheric pressure.
2. Atmospheric pressure can be increased above the normal resting alveolar pressure.

With normal inspiration, contraction of the respiratory muscles results in an enlargement of the thoracic cage and expansion of the lungs. This expansion reduces the pressure within the lungs and a pressure gradient of approximately 3 mm is established between the mouth and the alveoli. The result is a flow of atmospheric air into the lungs.

Consider a closed syringe, on which you pull back on the plunger thereby expanding the volume in the barrel. This is comparable to the expansion of the thorax by inspiratory muscular contraction. One readily recognizes the negative pressure that has been created within the syringe. If you open the syringe end, atmospheric air flows into the barrel, as it would flow from the mouth to alveoli during inspiration.



**FIGURE 23: MECHANICS OF VENTILATION**



## MUSCLES OF INSPIRATION

The principle muscle of inspiration is the diaphragm. It is a large dome-shaped sheet of muscle that separates the thoracic and abdominal cavities. In quiet relaxed breathing it may be the only muscle utilized. The diaphragm is anchored about the circumference of the thorax.

Muscular contraction results in a downward movement of the central part, similar to movement of a piston within a cylinder. The main action of the diaphragm is to enlarge the thoracic cavity downward. During maximum ventilation in a healthy individual, its excursion may be as much as ten centimeters. The motor nerves of the diaphragm exit from the spinal cord from the third to fifth cervical vertebrae and run downward as the phrenic nerves.

## ACCESSORY MUSCLES OF INSPIRATION

The intercostal muscles increase the anterior-posterior diameter of the thorax by moving the anterior end of each rib in an outward and upward motion. As well, their contraction tenses the intercostal spaces and keeps them from being sucked in during inspiration. These muscles are innervated by the intercostal nerves which leave the spinal cord between the first and eleventh thoracic vertebrae, corresponding with muscle position.



### Clinical vignette

You can now readily see that if the spinal cord is transected above C-3, all muscles of ventilation are paralyzed as there is a loss of nervous control. If the cord is injured below C-5, the diaphragm continues to work and some ventilation occurs.

Other important accessory muscles of inspiration, which come into play when ventilation is laboured, are the **scalenes** and the **sternocleidomastoids**. Contraction of these muscles function to raise the anterior end of the first rib, together with the manubrium and sternum. In addition to increasing the anterior dimension of the upper outlet of the thorax, this also stabilizes the upper thoracic cage so that contraction of the intercostal muscles results in elevation of the remaining ribs.

Maximal contraction of the inspiratory muscles of respiration can lower the intra pleural pressure to as much as 60-100 mmHg below atmospheric.

## MUSCLES OF EXPIRATION

Expiration is usually a passive process. Contraction of the inspiratory muscles causes the elastic tissues of the lungs and thorax to be stretched, and thus potential energy is stored in them. Expiration usually occurs as a result of the recoil of the stretched tissues and release of stored energy. Only at very high rates of ventilation (above 40 litres per minute), or with moderately severe airway obstruction (as seen in asthma or emphysema) do the muscles of expiration actively contract.

The abdominal muscles are the most important muscles of expiration. They include:

- o External obliques
- o Internal obliques
- o Rectus abdominus
- o Transversus abdominus.

Contraction of these muscles increases intra-abdominal pressure thereby moving the diaphragm upward. Additionally, contraction depresses the lower ribs thereby decreasing the circumference of the thorax.

Contraction of the internal intercostal muscles depresses the ribs, moving them downward and inward. They also stiffen the intercostal spaces so they do not "bulge out" during expiratory efforts such as coughing.

## RESPIRATORY REFLEXES

### 1. Cough

A cough is a violent expiratory blast against a partially closed glottis. The cough reflex is induced by irritation of sensory nerve endings in the larynx, trachea or the larger bronchi.

The actual stimulus may be:

- o Inflammatory **e.g.** infection
- o Mechanical **e.g.** dust, smoke
- o Chemical **e.g.** irritating, noxious gases
- o Thermal **e.g.** cold air.

Once the nerve endings are irritated, impulses are transmitted to the "cough centre" in the medulla. This triggers the following sequence of events:

1. Deep inspiration
2. Tight closing of glottis
3. Expiration against closed glottis
4. Glottis partially opens
5. Expulsion of foreign material.

The closing of the glottis allows for pressure to accumulate within the respiratory passages. The sequential partial opening of the glottis allows for rapid expiratory airflow and expulsion of the foreign substance.

## 2. **Sneeze**

The sneeze is a defence mechanism against irritant materials in the upper respiratory tract. Irritation of the sensory endings in the nasal mucous membrane results in a deep inspiration which is followed by a violent expiration, with the mouth closed, so that the expiratory blast is discharged through the nose.

## **PULMONARY COMPLIANCE**

Healthy lungs contain a great deal of elastic tissue. This must be stretched when the lungs expand. Elastance is defined as that property of matter which allows it to return to its original shape after having been deformed by some external force.

Compliance in pulmonary physiology usually refers to the amount of pressure that must be generated to expand the lungs with a given volume.

We all recognize that some balloons are harder to inflate than others; the same is true of lungs or even the same lung at different times. The more pressure that has to be exerted to inflate the lung, the less its compliance.

Clinically, compliance is of great importance. Decreasing compliance usually indicates increasing disease. Poorly compliant lungs are often referred to as "stiff", **e.g.** worsening interstitial pneumonia or increasing pulmonary fibrosis.

You will often note changes in compliance when you are manually squeezing a bag to ventilate a patient. If compliance is improving you'll need to exert less pressure to move the same volume of air.

Unfortunately in many clinical scenarios the reverse situation is encountered, **e.g.** a patient with increasing pulmonary edema will require greater pressure to move the same amount of air.

## **SURFACE TENSION**

If one imagines the cells of the alveoli wall, each having a fair amount of iron in their nucleus, and then pictures what would happen if a magnet were placed in the center of this alveolus - the walls would move inward. The closer the walls got to the magnet, the stronger would be the magnetic pull. This is a crude example to illustrate the essential nature of the force known as **surface tension**.

If one had to overcome the force of surface tension to expand the hundreds of millions of alveoli with each breath, it would require exhaustive muscular effort that could not be sustained over

long periods of time. Fortunately the alveolar cells produce a protein substance known as **pulmonary surfactant**. Surfactant dramatically reduces surface tension and consequently the muscular work required to expand the alveoli.

A striking example of the crucial nature of surfactant is seen in the disease known as Infant Respiratory Distress Syndrome (IRDS). It frequently strikes premature infants who, because of the physical immaturity of the surfactant producing cells, have insufficient surfactant present in their alveoli. As a result, the infant requires strenuous muscular effort to inspire. Treatment of this condition requires maintenance of a positive airway pressure to overcome the surface active forces present, instilling exogenous surfactant into the lungs, and in some instances mechanical ventilation.

## **MECHANICAL WORK OF BREATHING**

It can be demonstrated mathematically that there is an optimal tidal volume and respiratory frequency at which the mechanical work of breathing, and jointly the oxygen consumption, is minimal. It has been shown that both normal subjects, as well as those with pre-existing pulmonary disease, breathe at a tidal volume and frequency at which the work of breathing is least.

In the normal individual the respiratory muscles require between 3 - 14 mL of oxygen (<5% of the total body's oxygen consumption).

In severe cardiac or pulmonary pathological states, the oxygen cost of breathing can dramatically increase. For example, an emphysemic patient at rest may utilize 25% of his total oxygen consumption for the mechanical work of breathing.

Additionally cardiopulmonary pathologies will result in a disproportionate increase in oxygen consumption with increases in ventilation.

## LUNG VOLUMES AND CAPACITIES

It is important that the paramedic understand a few of the commonly used terms relating to lung volumes and capacities.

1. **Tidal Volume** ( $T_V$  or  $V_T$ ) is the measure of the volume of air inspired and exhaled with each breath at rest. In the healthy adult it is usually 400 - 500 mL, however it can be substantially higher.
2. **Residual Volume** is the air remaining after expiration. Even with a maximal expiratory effort, all the air can not be emptied from the lungs. This remaining air is the residual volume.
3. **Functional Residual Capacity** (FRC) is the volume of gas remaining in the lungs at the end of normal tidal exhalation. Note: A Positive End Expiratory Pressure, or P.E.E.P. device, limits exhalation (i.e. increases the FRC) and keeps the alveoli from collapsing.
4. **Total Lung Capacity** is the maximum amount of air the lungs can contain.
5. **Forced Vital Capacity** is the maximum amount of air that can be exhaled after a maximal inspiration.
6. **FeV<sub>1</sub>** (forced expiratory volume in one second). This is a measure of the amount of air that can be exhaled in the first second of a maximal forced exhalation. It is a very useful measure of the degree of obstruction present in asthma, **e.g.** the lower the FeV<sub>1</sub> the more severe the obstruction.

A reduction in the lung volumes obtained by spirometry suggest the presence of a "restrictive" type of pulmonary disease. This is, consistent with a reduced distensibility of the lungs as seen in pulmonary fibrosis, or a reduced distensibility of the chest wall symptomatic of kyphoscoliosis, and certain neurological diseases.

An increase in the measured lung volumes indicates that the lungs are hyperinflated because of obstruction of the airways (as in asthma), or a loss of lung elasticity (as in emphysema). Consistent with this loss of elasticity is a reduced ability to rapidly exhale the inspired air (decreased flowrates).



### Clinical vignette

"Spirometry is the process of measuring volumes of air moving in and out of the lungs. A spirometer is the device used to measure these volumes."

## CENTRAL NERVOUS SYSTEM CONTROL OF VENTILATION

Control of ventilation is principally governed by the respiratory center in the brainstem. It responds to increased blood CO<sub>2</sub> levels by increasing ventilation - increased respiratory rate (RR) and/or increased tidal volume. Ventilation decreases when our blood CO<sub>2</sub> level is below normal.

In patients with chronic markedly elevated CO<sub>2</sub> levels, the respiratory center may be inactivated. These people breathe based on their hypoxic drive. Hypoxia is sensed principally by the carotid and aortic arch chemoreceptors. When they are stimulated, the rate and/or volume of respiration is increased.

We also can exert a voluntary control over our respirations, **e.g.** breath holding.

Some drugs may directly stimulate the respiratory center resulting in hyperventilation, **e.g.** ASA toxicity. Many other drugs markedly depress our respiratory drive, **e.g.** narcotic or sedative overdoses.

Metabolic acidosis markedly stimulates our respiratory center resulting in hyperventilation. This lowers the blood's CO<sub>2</sub> content and will elevate the serum pH towards normal.

A wide variety of CNS insults result in abnormal respiratory patterns varying from apnea to central neurogenic hyperventilation, discussion of which is beyond the scope of this text.

## VENTILATION PERFUSION RATIO

Ventilation (V) is defined as the volume of air which moves into or out of the mouth. Minute ventilation (or volume) equals the number of breaths per minute times the volume of each breath ( $T_v$ ).

### EXAMPLE

lf:	Respiratory rate	= 12 breaths/min
	Tidal volume	= 500 cc
Minute ventilation		= 12 x 500 cc
		= 6000 cc per minute

Perfusion (Q) is defined as the flow of blood through tissues. At rest the normal cardiac output is approximately 6L/min, **i.e.** the lungs are perfused with 6L of blood per minute.

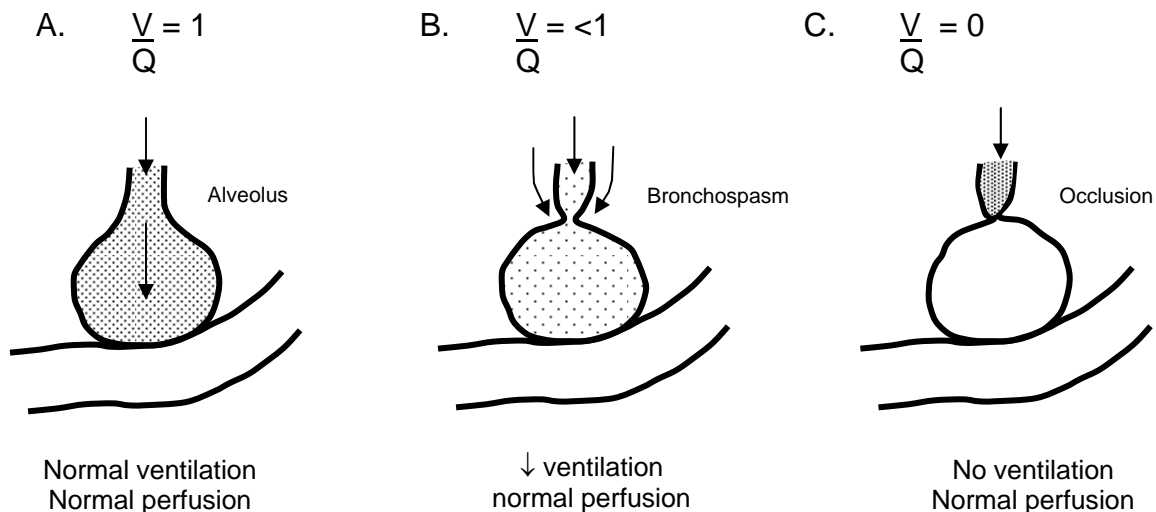
The ventilation perfusion ratio, (ventilation/perfusion) is commonly expressed as  $V/Q$  or  $V:Q$ .

Under ideal conditions:

$$V = Q$$

Anything that decreases the amount of air entering an area of lung tissue will decrease its  $V/Q$  ratio ( $V/Q < 1$ ), **e.g.** 5L V/6L Q = .83. If no air can enter a segment of lung then its  $V/Q = 0$  (since 0 divided by any number is still 0) – **e.g.** foreign body obstruction (FBO) of the airway.

**FIGURE 24: VENTILATION/PERFUSION RATIO**



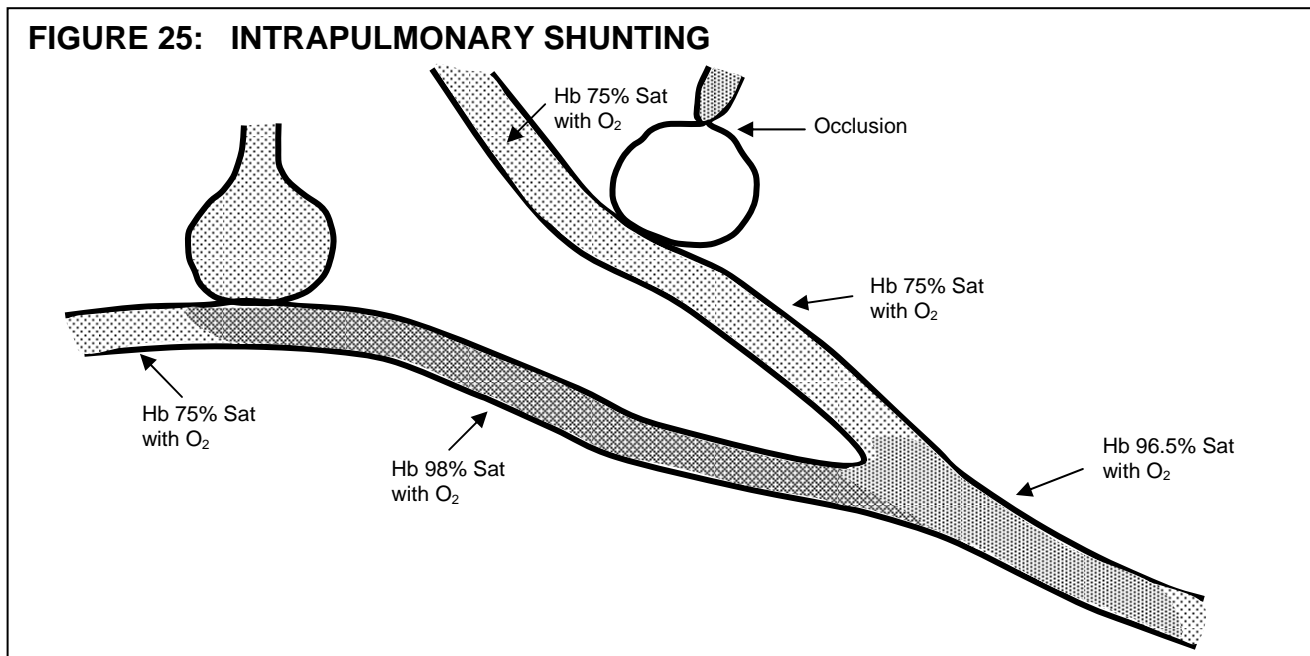


A common clinical example of a ventilatory disorder causing V/Q mismatch is in the asthma patient. When totally well, his V/Q = 1 (Figure 24A). As bronchospasm increases, less air can be moved into his alveoli, therefore, V/Q < 1 (Figure 24B). If his condition worsens and some airways become totally occluded (often due to bronchospasm and mucous plugging), no ventilation of these alveoli occurs, therefore, V/Q = 0 (Figure 24C).

Intrapulmonary shunting occurs with any illness that permits blood to flow through the lungs without picking up enough O<sub>2</sub> to fully saturate the hemoglobin. A shunt will result in a decreased arterial oxygen concentration.

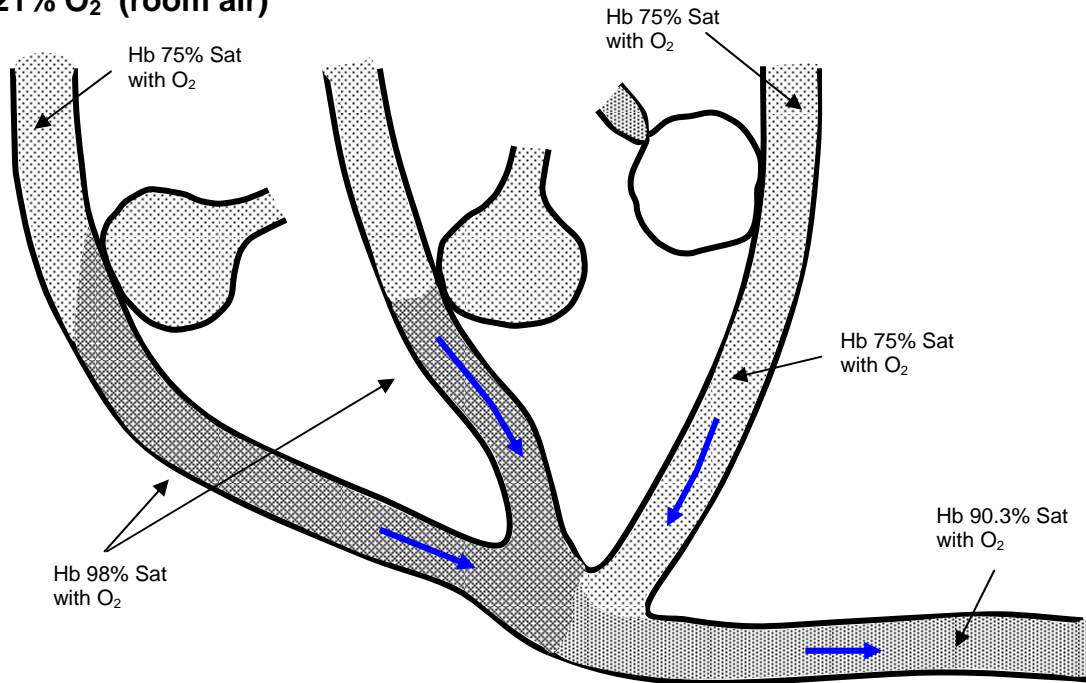
Abnormalities of decreased perfusion, **e.g.** secondary to a large myocardial infarction will result in less blood being circulated around the ventilated alveoli. Because of this, less than normal amounts of oxygen are extracted from the alveoli. One can quickly appreciate that if the cardiac output is reduced by one third, **e.g.** 4 instead of 6 L/min, then only two-thirds as much oxygenated blood can be delivered to the tissues, despite normal ventilation.

One should now be able to recognize two types of V/Q mismatch leading to tissue hypoxia that will not respond well to increasing the percentage of inspired oxygen. In the circumstance where a large amount of intrapulmonary shunting is occurring and a large volume of poorly oxygenated blood is being mixed with maximally oxygenated blood, the amount of oxygen available for tissue metabolism will still be less than normal (Figure 26).

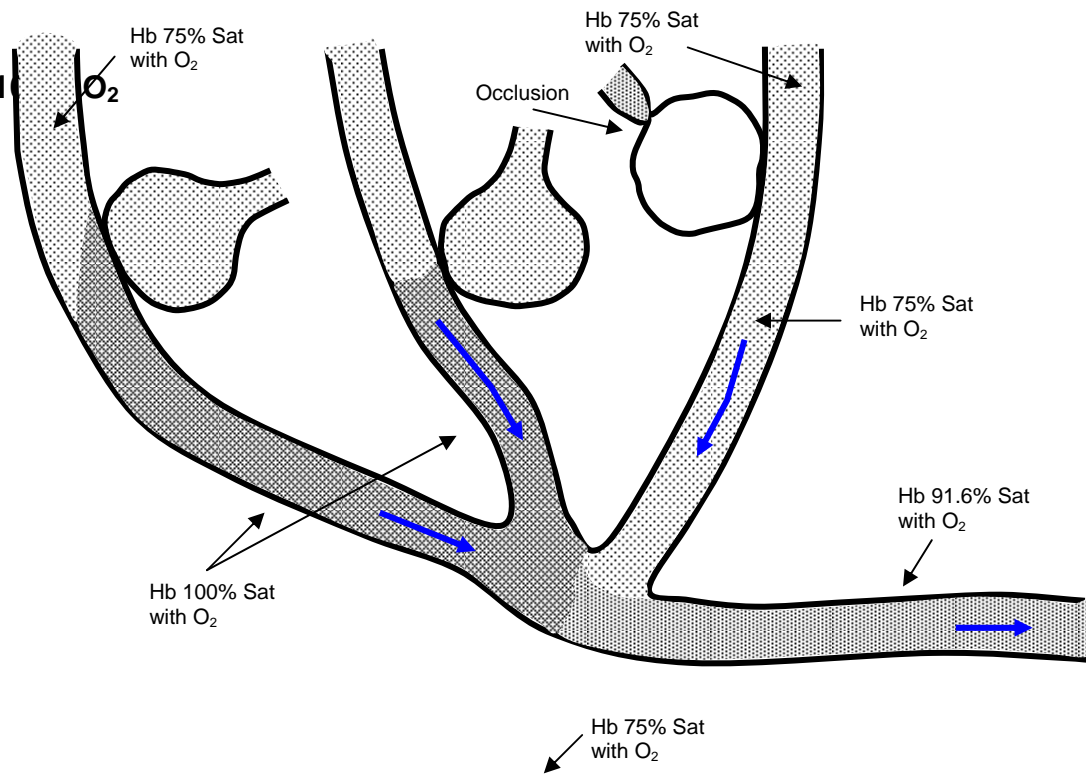


**FIGURE 26: EFFECT OF INCREASING INSPIRED O<sub>2</sub> CONCENTRATION**

**A. 21% O<sub>2</sub> (room air)**



**B. 100% O<sub>2</sub>**





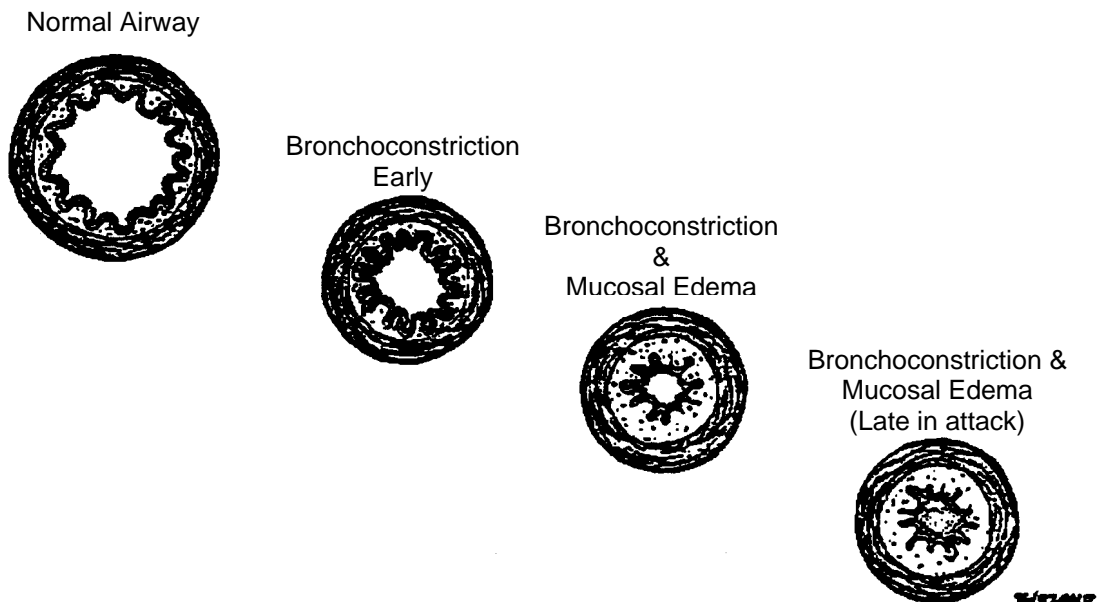
# COMMON RESPIRATORY ILLNESSES

## ASTHMA

Asthma is defined by the American Thoracic Society as a “chronic inflammatory disease of the airways” and is characterized by increased responsiveness of the trachea and bronchi to various stimuli and manifested by widespread narrowing of the airways that changes in severity either spontaneously or as a result of therapy.

Early in an acute asthmatic attack, the airway narrowing is caused by smooth muscle contraction. As the attack continues, further airway narrowing results from mucosal edema and increased mucous production. This may progress to total obstruction of peripheral airways.

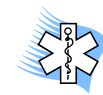**FIGURE 27: CROSS SECTION OF THE AIRWAY**



An attack of asthma may be triggered by many stimuli. Some of the more common are allergens, infections, cold temperatures and exercise.

The symptoms early in an acute asthmatic attack consist of dyspnea, wheezing and cough. The physical findings may consist of cough, anxiety, tachycardia, increased respiratory effort including use of accessory muscles, nasal flaring, and inability to lie down. Inspiratory and expiratory wheezing (due to large and small airway constriction) will be heard in the asthma patient that is still ventilating adequately. Prolongation of the time required for inspiration and expiration is usually evident in these patients.

If an attack is allowed to progress and worsen, the severity of the symptoms and signs will increase. However the patient's ability to compensate for increased airway narrowing by increasing respiratory effort is finite. When this is exceeded, respiratory effort decreases; the patient becomes confused (decreased O<sub>2</sub> and increased CO<sub>2</sub>); wheezing decreases (the worst asthmatics have silent chests); and unless rapid intervention occurs, respiratory arrest followed by cardiac arrest is imminent.



### Clinical vignette

The number of words the patient is able to speak between breaths is a good indicator of disease severity. e.g. 2-word dyspnea would likely signify moderate to severe respiratory distress.

## Chronic Obstructive Pulmonary Disease (COPD)

COPD is generally used to describe patients who have chronic airway obstruction. Chronic is defined as occurring on most days for at least three months in the year, for at least two successive years.

The causes of airway obstruction that fall within the COPD basket are emphysema, bronchitis and asthma.

**Emphysema** is defined as a condition of the lung characterized by abnormal, permanent enlargement of the air spaces distal to the terminal bronchiole, accompanied by destruction of their walls.

**Bronchitis** is defined as chronic or recurrent excess mucous secretion in the bronchial tree, in most instances accompanied by cough.

**Asthma** is defined as a chronic inflammatory disease of the airways with hyperreactivity of the trachea and bronchi to various stimuli and manifested by widespread narrowing of the airways that changes in severity either spontaneously or as a result of therapy.

Most patients with COPD have a combination of all three of these illnesses, although the fraction that each contributes to the respiratory obstruction varies from patient to patient, **e.g.** patient A's obstruction may be predominantly due to bronchitis and bronchospasm with no emphysematous component, while in patient B the obstruction may be due to emphysema and bronchitis with no bronchospasm. Many other combinations of the three illnesses are possible.

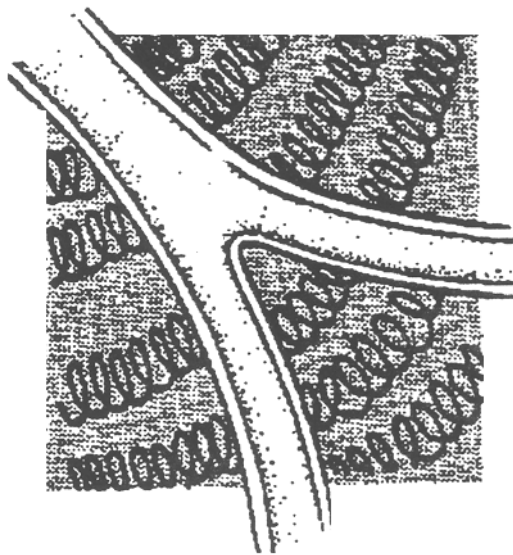
As the combination of the illnesses leading to airway obstruction varies, so do the symptoms and signs and frequency of exacerbations.

In order for you to assess how much of each illness is responsible for **your individual** patient's respiratory obstruction, you must understand the presentation of each illness in its pure form. However, you must also realize that in **most** COPD patients, respiratory obstruction is due to a combination of two or three of these illnesses.

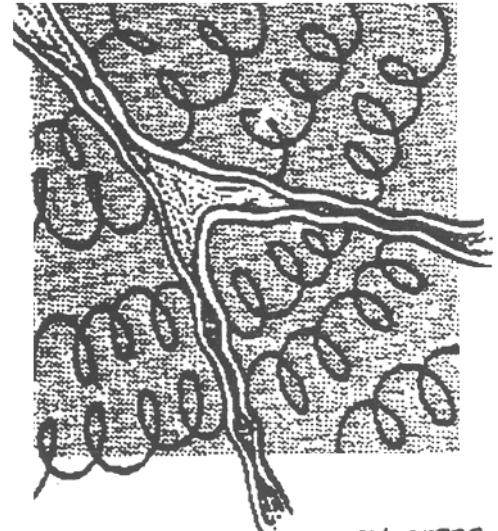
## EMPHYSEMA

Patients with emphysema have had significant destruction of their alveolar septa (walls) and obliteration of the pulmonary vascular bed. The alveolar septa are the springs that keep the bronchi open. Without their support, the bronchioles collapse.

**FIGURE 28: MECHANISM OF BRONCHIOLAR COLLAPSE IN EMPHYSEMA**



Normal elastic support



Decreased elastic support (emphysema)

This collapse of airways leads to two problems:

- o Increased air flow obstruction
- o Overinflation of the air sacs.

The classic picture of patient whose COPD is caused only by emphysema is that of the pink puffer. These patients are thin, anxious, alert, oriented, dyspneic, tachypneic and hyperventilating. Dyspnea is the hallmark.

Accessory muscles of breathing are used in the fight for breath. Pursed lips on expiration increases airway pressure, thereby internally splinting the airway. These patients have minimal respiratory reserve and are largely sedentary. Due to the chronic over distension of their airways, these patients have increased A/P chest diameters and low immobile diaphragms. They usually have normal colour (pink) and near normal arterial blood gases.

Unfortunately, due to their poor respiratory reserve, many patients with severe emphysema can not tolerate any increased respiratory insult. A pneumonia or even a single fractured rib may tip

them into respiratory failure. Excessive coughing in emphysemics can also lead to barotrauma such as a pneumothorax. Markedly diminished or absent air entry in a dyspneic emphysemic may signal a tension pneumothorax and is an ominous sign!

Unfortunately there is no therapy short of lung transplantation to correct emphysema.

## **BRONCHITIS**

Patients whose COPD is due solely to chronic bronchitis are often referred to as "blue bloaters". This refers to chronic central cyanosis due to the shunting (V/Q mismatch) that occurs in the lung, resulting in ↓ O<sub>2</sub> saturation. This person is relatively stocky or obese and has central and peripheral cyanosis. They have less of an increase in their A/P chest diameter than the emphysematous patient, and their diaphragms are not abnormally low. They usually have a chronic cough, often productive of sputum.

These patients may deteriorate suddenly (over a few minutes) and if they do, either a pneumothorax, pulmonary embolism or atelectasis is usually the cause. The atelectasis is caused by secretions obstructing a major airways.

Increasing secretion production causes a more gradual deterioration. This is usually due to an "allergic cause" or infection. Pneumonias can be devastating in these patients. One must be even more wary of rib fractures in the "blue bloater" than the "pink puffer". If these people don't cough vigorously they don't clear their secretions and substantial airway collapse may occur.

We have already discussed the third illness in the triad causing COPD, **i.e.** asthma.

# MANIFESTATIONS OF RESPIRATORY DISEASE

## SYMPTOMS AND SIGNS

### EXCESSIVE NASAL SECRETIONS

This may be the result of irritation of the mucosa of the upper respiratory tract due to infection, allergens, or mechanical or chemical sources.

### SNEEZING

Forced exhalation of air through the nose is an attempt to remove nasal mucosal irritants.

### COUGHING

Coughing is a defense mechanism of the lower respiratory tract, functioning to clear airways of irritants. The initiating stimulus may be:

- o inflammatory, **e.g.** infection, asthma
- o mechanical, **e.g.** dust, aspirated material
- o chemical, **e.g.** irritating noxious gases, smoke, Cl<sub>2</sub>
- o thermal, **e.g.** cold air.

Coughing may become chronic in nature, **e.g.** bronchitis.

### EXPECTORATION OF SPUTUM OR BLOOD

It is important to determine colour, volume, and consistency of sputum. For example:

- o duration of sputum production will indicate an acute or chronic disease process
- o mucoid, sticky, grey or white sputum may be normal for persons with COPD, **e.g.** chronic bronchitis
- o yellow or green sputum may indicate infection
- o blood may be mixed with sputum in varying degrees or it may comprise the entire expectorate.

### CHEST PAIN

Determining the exact cause of chest pain is often difficult. One should know the possible sources of chest pain and the usual type of pain produced by each. Sources of chest pain are:

### CHEST WALL

- o Skin, **e.g.** burns - this is constant, mild to excruciating in nature
- o Ribs, **e.g.** fractures - usually associated with trauma and increased by anything that moves the rib(s), **e.g.** breathing/movement/palpation, moderate to severe in nature



- Costal cartilages, **e.g.** costochondritis - similar to pain of rib fracture but less severe
- Muscles, **e.g.** muscle sprain - similar to pain of rib fractures, especially sore when using involved muscles, mild to moderate in severity
- Nerves, **e.g.** shingles (Herpes Zoster) - constant boring, burning pain, maximal in the involved dermatome, mild to moderate in severity.

## PLEURA

- Pleuritic pain is stabbing, knifelike, aggravated by breathing, movement and coughing. This pain is usually moderate to excruciating. Common causes of pleural irritation are infections, **e.g.** pleurisy and pneumonia, or pulmonary infarctions.

## PERICARDIAL

- This pain is often similar to pleural pain in nature and often worsened by breathing. It is commonly decreased when leaning forward. Pericardial inflammation is usually due to pericardial infection or subsequent to myocardial infarction. Moderate to severe.

## DIAPHRAGM

- Pain similar in character and severity to pleural pain is due to diaphragmatic irritation from above, **e.g.** lower lobe pneumonia or pulmonary infarction, or below, **e.g.** free peritoneal blood or air. This is often associated with referred pain to one or both shoulders.

## ESOPHAGEAL IRRITATION

- This pain can vary from the burning associated with heartburn to pain indistinguishable from that of myocardial infarction, mild to severe in nature.

## CARDIAC ISCHEMIA

- This is extensively described elsewhere. Classically described as tightness, heaviness, pressure, weight originating from center of chest. It may radiate to arms and/or neck and jaw and occasionally to the back. This pain is not increased with chest movement or breathing. It may be associated with sweating, nausea and/or vomiting.

## AORTIC DISSECTION

- Sudden onset of severe centralized chest pain is the most common complaint. The pain often begins in the anterior chest and may “migrate” to the interscapular region and/or down the back. In fact, migrating pain is highly specific to thoracic aortic dissection. It may also be described as a “ripping” or “tearing”. One article reported that 71% of patients had migration of pain with their dissections.<sup>1</sup>

It is often associated with sweating, nausea and vomiting. A difference in systolic blood pressures between the right and left arm of  $\geq 15$  mmHg may suggest the aortic dissection has taken a path along one of the subclavian arteries. Hypotension is an ominous sign.

## ESOPHAGEAL RUPTURE

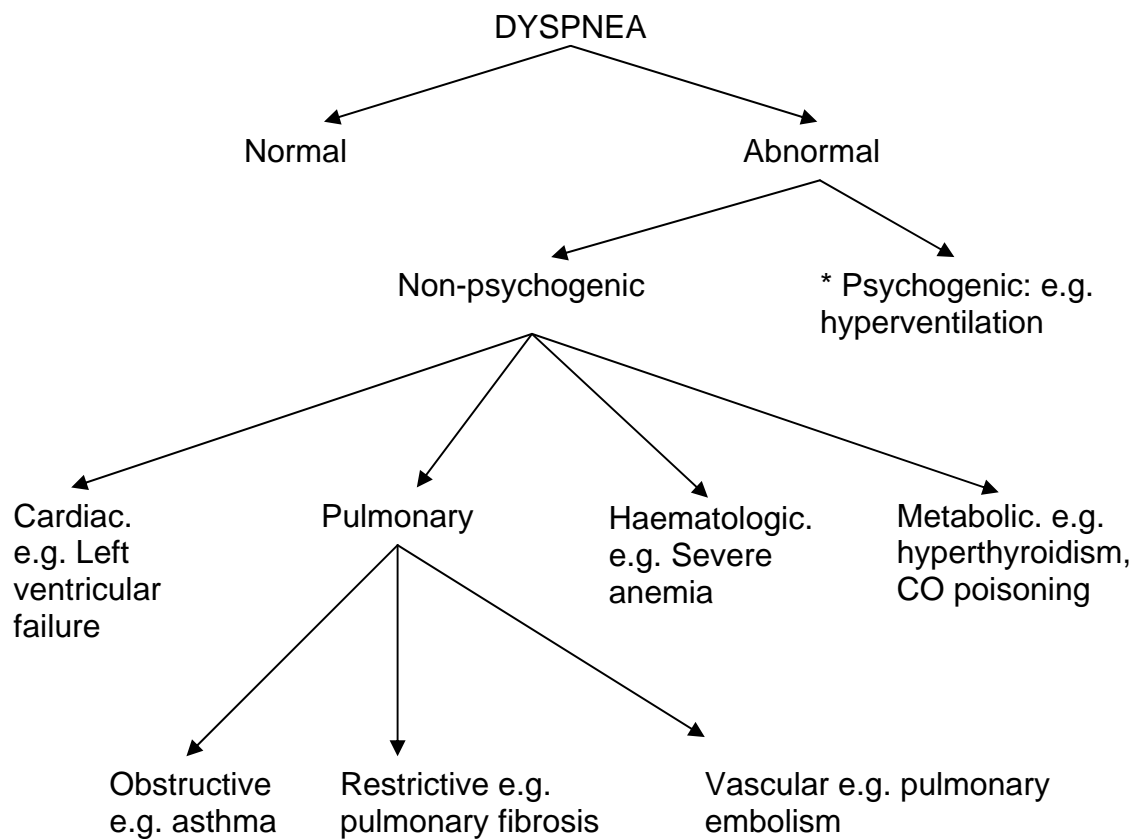
- o This is a rare occurrence and usually occurs as the result of an instrument being introduced into the esophagus for medical purposes. Signs & symptoms include severe central chest and/or epigastric pain that is usually preceded by a sudden increase in intrathoracic pressure, **e.g. of other causes:** vomiting, violent coughing, weight lifting **e.g. of instrumentation:** insertion of esophageal/airway device, gastric lavage, esophagoscopy. The pain is often pleuritic in nature but may be constant. It may radiate to the back and is often increased by swallowing or neck movement.
- o You will already have noted that the pain associated with chest wall, pleural, pericardial and diaphragmatic hernia or esophageal rupture share common features. Differentiation is often very difficult.

## DYSPNEA

Dyspnea is defined as a sensation of difficulty breathing. This may be normal or abnormal, **e.g.** the dyspnea associated with bronchospasm, COPD, chest wall injury or foreign body obstruction. The causes of abnormal dyspnea may be:

- o Physical, causes of which include anything that increases the body's O<sub>2</sub> consumption or decreases its ability to deliver O<sub>2</sub> to the tissues.

**FIGURE 29: CAUSES OF DYSPNEA**



## SHORTNESS OF BREATH (SOB)

Conversely, shortness of breath is the subjective sensation of not being able to catch one's breath. e.g. as might be experienced in the setting of hypovolemia where oxygenation is inadequate due to hypoperfusion and decreased oxygen carrying capacity from lost red blood cells. Or, the SOB experienced by some in the setting of acute myocardial infarction where cardiac output, and consequently tissue perfusion and oxygenation is impaired. In the healthy state, SOB may occur with exercise.

## HYPOXIA

Hypoxia is defined as a lack of sufficient  $O_2$  to allow proper functioning of the brain and other vital organs and tissues. Hypoxia can result from:

- o Respiratory causes, **e.g.** severe pulmonary edema
- o Cardiovascular causes, **e.g.** cardiogenic shock or hypovolemia
- o Haematological causes, **e.g.** severe anemia or CO poisoning.

As the definition implies, CNS signs are often prominent in hypoxia. These may range from anxiety, combativeness, visual disturbances, in-coordination and dysarthria to confusion or coma and even seizures. Other signs of hypoxia may include cyanosis, cardiac arrhythmias and signs of sympathetic stimulation such as tachycardia and diaphoresis.

Hypoxia is a major stimulant of respiration when the  $PaO_2$  falls to below 60 mmHg (normal  $PaO_2$  is 80-100 mmHg). However, in severe pre-terminal hypoxia, spontaneous respiration may be absent. Correction of hypoxia takes highest precedence in the treatment of any patient.

## CYANOSIS

Cyanosis is defined as a diffuse bluish discoloration of the skin and mucous membranes, secondary to an increased amount of deoxygenated (reduced) hemoglobin in the bloodstream. Approximately 5 g deoxygenated hemoglobin per 100 ml of blood, or the presence of abnormal hemoglobin (methaemoglobin or sulfhaemoglobin), is required to produce cyanosis in normal persons. Polycythemic patients (those with abnormally high red blood cell count [hemoglobin]) may exhibit cyanosis at lower levels.

Cyanosis is usually a late sign of hypoxia.

## HYPERCAPNIA

An increased blood level of carbon dioxide ( $PaCO_2$ ) results when ventilation is insufficient to remove the carbon dioxide produced. Most hypercarbic patients are **hypoventilating**. The common causes are:

- o decreased central respiratory drive, **e.g.** narcotic OD
- o spinal cord transection
- o Neuromuscular diseases, **e.g.** myasthenia gravis.
- o COPD (chronic  $CO_2$  retainers)

Hypercarbia can, however, occur in the presence of an increased respiratory rate and effort, **e.g.** severe asthma. These patients are also in great danger as despite maximal ventilatory effort, they cannot compensate for their respiratory disease.

Hypercarbic patients may complain of a headache (increased PaCO<sub>2</sub> produces cerebral vasodilation) and if the CO<sub>2</sub> level continues to rise, the patient may become confused, somnolent or comatose.

#### References:

1. Sarasin FP, Louis-Simonet M, Gaspoz, J-M, et al. **Detecting acute thoracic aortic dissection in the emergency department: Time constraints and choice of the optimal diagnostic test.** *Ann Emerg Med* 1996;28:278 -288.

**ADVANCED LIFE SUPPORT  
PRECOURSE  
RESPIRATORY SYSTEM**

**SELF-ASSESSMENT**

**MARKS**

[2] 1. You have unsuccessfully attempted a nasotracheal intubation and now have a substantial epistaxis from the same nostril. What two general sites are the most likely to have been injured?

---

---

2. You are attempting a blind nasotracheal intubation on a different patient (without the use of a laryngoscope). This patient has presented with hypoventilation secondary to a drug overdose. The tube advances without difficulty but does not enter the trachea.

[1] a) What is the most likely anatomic location of the distal end of the tube at the end of the unsuccessful pass?

---

---

[2] b) Your intubation attempt has stimulated the patient's rate and depth of ventilation. Without using any instruments or tools, how would you know that the tube is not in the trachea?

---

---

[2] 3. List in order of anatomical position the following structures, starting with the most anterior:

- a) esophagus \_\_\_\_\_
- b) vertebral body \_\_\_\_\_
- c) larynx \_\_\_\_\_
- d) spinal cord \_\_\_\_\_

[3] 4. At the cephalic end of the trachea is a) \_\_\_\_\_.

The trachea terminates at the bifurcation into the mainstem bronchi. This area is called b) \_\_\_\_\_. The trachea is usually c) \_\_\_\_\_ in length.

5. On arrival at hospital, the emergency physician tells you that your patient's endotracheal tube was in a mainstem bronchus.

[2] a) Is this desirable? Explain your answer.

---

---

---

---

---

---

---

[1] b) Name the most likely mainstem bronchus involved.

---

[2] c) What is the anatomical reason for this position?

---

[1] d) This same patient exhibited enroute to hospitals an increasing degree of cyanosis and an increased heart rate. The most likely cause is \_\_\_\_\_.

---

[2] e) You have increased the oxygen concentration administered to this patient in response to d). Will the patient respond positively to this? (Justify your answer in 10 words or less.)

---

---

---

6. You are called to the scene of a karate tournament where a combatant is having a great deal of difficulty breathing following a blow to the anterior neck.

[1] a) Identify the vulnerable structure most likely involved.

---

---

[2] b) Identify the risk to the patient and the mechanism by which it occurs.

---

---

---

[3] 7. Anatomically orient the following structures starting with the most cephalad:

- Thyroid cartilage \_\_\_\_\_
- Hyoid bone \_\_\_\_\_
- Tracheal rings \_\_\_\_\_
- Cricoid cartilage \_\_\_\_\_
- Mandible \_\_\_\_\_
- Cricothyroid ligament. \_\_\_\_\_

[2] 8. a) Why do very sick asthmatics often have very little wheezing?

---

---

---

---

[1] b) What causes the wheezing in asthma?

---

---

---



9. A patient presents in a restaurant with a piece of food stuck in mid-esophagus.

[1] a) The potential for airway obstruction (exists/does not exist) \_\_\_\_\_  
\_\_\_\_\_.

[2] b) Give the anatomical reason for your answer.

---

---

---

[3] 10. Name the three pathologies involved in COPD.

---

---

---

[1] 11. You are ventilating an intubated patient with asthma and COPD. You are noticing that you have to use increasing force to move the air. Using medical terminology (two words) state what is happening.

---

---

12. You notice that the nasal secretions of a patient who has suffered a severe head injury are seen to consist of dilute blood. When this falls on the sheet it is seen to form a dark red inner circle and a pink outer circle.

[1] a) What is the likely anatomic site of injury?

---

[1] b) Name the secretion.

---

[1] c) What are the implications in terms of choice of airway protection?

---

---

---

---

[1] 13. You have a patient with a C-3 cord transection. Describe the nature of this patient's respiratory effort.

---

---

---

[1] 14. a) Define tidal volume.

---

---

[1] b) What is the normal adult range?

---

40 TOTAL SCORE

**ADVANCED LIFE SUPPORT  
PRECOURSE  
RESPIRATORY SYSTEM**

**SELF-ASSESSMENT ANSWERS**

1. Nasal septum  
Turbinates
2. a) Esophagus  
b) No air movement would be felt or heard.
3. Larynx Esophagus Vertebral body Spinal cord
4. a) cricoid cartilage  
b) the carina  
c) 10 cm
5. a) This is not desirable since air will only enter one lung. The result will be a hypoxic patient.  
b) Right  
c) The right mainstem bronchus is almost in a straight line with the distal end of the trachea, while the left mainstem bronchus takes a much sharper turn.  
d) Hypoxia  
e) Anticipate no response. You have created a large shunt.
6. a) Larynx  
b) Airway obstruction due to mucosal swelling, or mechanical obstruction.
7. Mandible  
Hyoid bone  
Thyroid cartilage  
Cricothyroid ligament  
Cricoid cartilage  
Tracheal rings
8. a) The production of sound is dependent upon adequate ventilation. Decreased ventilation, movement of air results in decreased wheezing. Decreased movement of air results from bronchoconstriction, mucosal edema and increased mucous production which causes obstruction of flow.  
  
b) Airway constriction.

9.
  - a) Exists
  - b) Tracheal rings are horseshoe-shaped, open at the posterior aspect. A large object in the esophagus could then protrude into the posterior aspect of the trachea.
  
10. Asthma  
Bronchitis  
Emphysema
  
11. Decreasing compliance.
  
12.
  - a) Cribriform plate (with or without basal skull fracture).
  - b) CSF
  - c) Anything put into the patient's nose is done with the risk of penetrating the cranium via the cribriform plate. In this instance if the oral route of airway support is possible, it is preferable.
  
13. None. Ventilatory support is required.
  
14.
  - a) Volume of air inspired and expired at rest.
  
  - b) 400-500 mL

ADVANCED LIFE SUPPORT  
PRECOURSE  
THE RESPIRATORY SYSTEM

EVALUATION

Upon completion of this module, please fill in and return this form to your base hospital co-ordinator.

Your comments will help to ensure that this unit is a useful learning module. Please indicate any problems that you may have encountered. All suggestions for improvement are welcomed.

1. How long did it take to complete this module? Please estimate.

Reading \_\_\_\_\_ hours  
Self assessment \_\_\_\_\_ hours  
Total time \_\_\_\_\_ hours

2. Were the objectives of the module clearly stated?

yes  no  
If no, please comment.

3. Did you see any of the resource materials?

yes  no  
If yes, which items

\_\_\_\_\_  
\_\_\_\_\_  
\_\_\_\_\_  
Were they helpful? \_\_\_\_\_

4. Were the reference notes adequate?

yes  no  
If no, please comment.

5. Were the reference notes easy to follow?

yes  no

If no, please comment.

6. Were the examples provided satisfactory?

yes  no

If no, please comment.

7. Were any of the self-assessment questions poorly worded?

yes  no

If yes, please specify.

1. Was the level of the module satisfactory for your program of study?

yes  no

If no, please comment.

Base Hospital \_\_\_\_\_

9. General comments or suggested improvements.