



Paramedic Resource Manual

NERVOUS SYSTEM SECTION SEVEN

2014 Update by
Ontario Base Hospital Group Education Subcommittee

OBJECTIVES: NERVOUS SYSTEM

The objectives indicate what you should know, understand and be prepared to explain upon completion of this module. The self-assessment questions and answers will enable you to judge your understanding of the material.

Upon completion of this module, the student should be able to:

1. Locate and describe the functions of the components of the central nervous system (the spinal cord and major parts of the brain).
2. Locate and briefly describe the protective/nutritive aspects of the central nervous system:
 - a) Skull
 - b) Meninges
 - c) Vertebrae
 - d) CSF
 - e) Circulation.
3. Briefly describe the somatic and autonomic nervous systems in terms of:
 - a) Neuronal components
 - b) Sympathetic and autonomic components
 - c) Control mechanisms
 - d) Effects on the major organs and body systems.
4. Briefly describe the neuron and the mechanism by which impulse transmission occurs.
5. Identify and locate the common neurotransmitters.
6. State and differentiate between the two major types of pain.
7. State the functions of pain.
8. Identify the components of the nervous system and factors responsible for influencing:
 - a) Consciousness, wakefulness and cognitive function
 - b) Decreased levels of consciousness and coma.
9. identify the components of the accepted assessment tool for evaluating brain function.
10. define and briefly describe reflex action, identifying the reflexes tested by prehospital personnel.
11. Identify the most vulnerable areas of the central nervous system in terms of illness and injury.
12. Describe and explain the mechanics of increased intracranial pressure.

13. Describe briefly the pathology associated with seizures, TIA's, CVA's, the major intracranial bleeds, head injury, spinal cord injury.

If you have studied this subject previously, you may test your ability using the self-assessment questions at the end of each section. If you are able to obtain 90% or greater, you may choose not to do the unit and merely review the section, or parts of sections, where weakness may exist. If you obtain less than 90%, it is recommended that the module be done in its entirety, stressing areas where more review is needed.

GLOSSARY

ACTION POTENTIAL	synonym for nerve impulse
AFFERENT	conducting toward a central site of reference
ATROPHY	wasting
AXON	nerve cell appendage along which impulses travel away from the nerve cell body
CLEFT	a fissure or longitudinal opening (as in synaptic cleft)
CONDUCTIVITY	the capacity to convey energy, e.g. impulse
CONSTRIC	to narrow or compress
CONVULSION	a series of involuntary contractions of the voluntary muscles
CVA	cerebral vascular accident, i.e. problem pertaining to the blood vessels of the brain
DENDRITE	tree-like processes composing most of the receptive surface of a neuron
DILATE	to stretch a structure or orifice
EDEMA	an abnormal accumulation of fluid in the interstitial spaces of the body
EFFERENT	conducting or progressing away from a central site
EMBOLUS	a clot or other plug brought by the blood from another vessel and forced into a smaller one leading to the obstruction of circulation
EXCITABILITY	readiness to respond to a stimulus – irritability
HEMATOMA	a localized collection of extravasated blood, usually clotted, in an organ, space or tissue
HEMIPARESIS	slight or incomplete paralysis affecting one side of the body
HEMIPLEGIA	paralysis of one side of the body


HEMISPHERE	half of a spherical or roughly spherical structure or organ
HOMEOSTASIS	a tendency of biological systems to maintain stability while continually adjusting to conditions that are optimal for survival
ICP	<ul style="list-style-type: none"> o intracranial pressure o measured as the pressure of the fluid in the subarachnoid space
IMPULSE (NERVE)	the electrochemical process propagated along nerve fibres
INTRACEREBRAL	within the cerebrum
INTRACRANIAL	within the cranium (skull)
INVOLUNTARY	performed independently of conscious will
ISCHEMIA	the deficiency of blood in a part, due to a total or partial obstruction of a blood vessel
LESION	a broad term referring to any pathological or traumatic discontinuity of tissue or loss of function of a part
MYELIN	a lipid substance forming a sheath around the axons of certain nerve fibres
NEURON	nerve cell
NEUROTRANSMITTER	a substance released into the synaptic cleft between an axon and the target cell can either excite or inhibit the target cell
PERIPHERY	the portion of a system outside the central area
PERMEABLE	permitting passage of a substance
PRODROMAL	symptom indicating the onset of a disease
PSYCHOMOTOR	pertaining to motor effects of cerebral activity
RECEPTOR	a site on the surface or within a cell that recognizes and binds with specific molecules, or a sensory nerve ending that responds to various stimuli
REFLEX SPASTICITY	a particular automatic response mediated by the nervous system abnormally increased muscle tone causing a continuous resistance to stretching

THROMBUS	an aggregation of blood factors frequently causing vascular obstruction at the site of its formation
TIA	transient ischemic attack
VISCERA	large interior organs in any of the great body cavities
VOLUNTARY	accomplished in accordance with will

INTRODUCTION

Although nervous system tissue accounts for only 3% of total body weight, it functions to **activate, control** and **integrate** all of the systems in the body. It receives information regarding changes in the internal and external environment and initiates and regulates the appropriate response to the stimulus. Thus the nervous system plays an important role in maintaining homeostasis.

FIGURE 1: INTEGRATION AND CONTROL BY THE NERVOUS SYSTEM

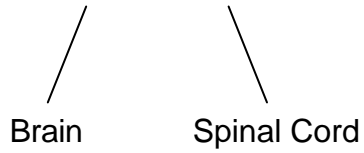


The nervous system can be classified by either location or by method of control. Anatomically it is divided into the **Central Nervous System (CNS)** and the **Peripheral Nervous System (PNS)**. Functionally, the peripheral nervous system is divided into the **Somatic Nervous System (SNS)**, which is under voluntary control, and the **Autonomic Nervous System (ANS)**, which is involuntary.

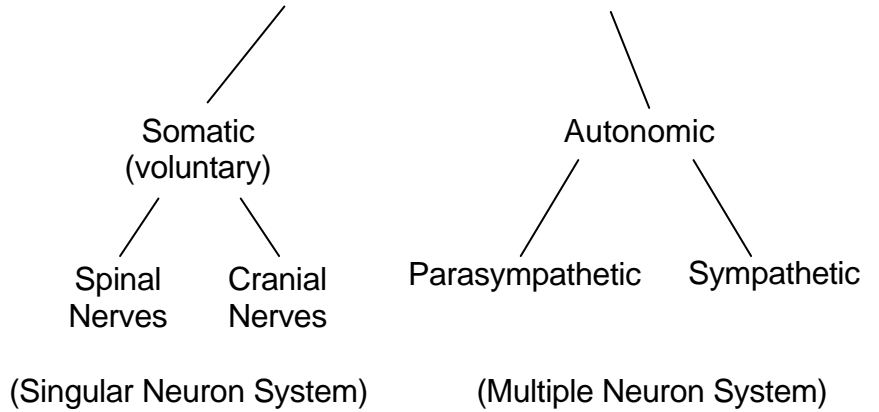
SUMMARY

CLASSIFICATION OF NERVOUS TISSUE

CENTRAL NERVOUS SYSTEM



PERIPHERAL NERVOUS SYSTEM



CENTRAL NERVOUS SYSTEM

The Central Nervous System (CNS) consists of the brain and spinal cord. These areas are of major importance in the nervous system as a whole. As you progress through this material keep the following facts in mind:

- The effects of CNS injuries depend on the location and extent of the damage sustained.
- It may be possible to deduce the nature of an injury by observing what abilities are missing or compromised.
- Functional losses may be permanent when the CNS is injured, since CNS tissue is unable to regenerate.
- Both the brain and spinal cord are surrounded by bone and protective membranes (the meninges).

THE BRAIN

The brain is the largest and most complex mass of nervous tissue. It is housed within a bony structure, the skull, which is a relatively “closed-box”. The brain does not achieve its final size (3-4 kg) until approximately the twentieth year. With age, the brain loses size and weight as it undergoes various degrees of atrophy.

The divisions of the brain that we shall consider are the **cerebrum**, **cerebellum**, and the **brain stem**. In addition, other structures of note are the thalamus, hypothalamus, pituitary gland, ventricles, skull and meninges.

CEREBRUM

The **cerebrum** is the largest part of the brain and is divided into right and left hemispheres. One hemisphere is dominant over the other in intellectual and motor functions. These cerebral hemispheres are connected and communicate through a structure call the **corpus callosum**.

The cerebrum has another layer of **gray matter**, composed of nervous tissue cell bodies and dendrites. This covering is called the **cerebral cortex**. Beneath the cortex is the cerebral medulla, more commonly referred to as **white matter**. This is an area of myelinated axons that interconnect neurons both within the nervous system and with other body parts.

The surface of the cerebral cortex is marked by ridges and grooves (**gyri**) and is divided into lobes by spaces called **sulci**. There are four distinct lobes in the cerebrum which correspond in name to the bones of the skull located adjacent to these areas – **frontal**, **parietal**, **temporal** and **occipital**.

The functions of the cerebrum are complicated, numerous and not fully understood as yet. It is known to be involved in such intellectual activities as interpretation of sensory impulses, control of voluntary muscles, storage of memory, thought and reasoning.

The **anterior aspect** of the frontal lobe deals with the elaboration of thought and correlates different types of information into a coherent sequence of action, **e.g.** decision making. The motor ability for speech, **i.e.** muscle control, is also centered in the area.

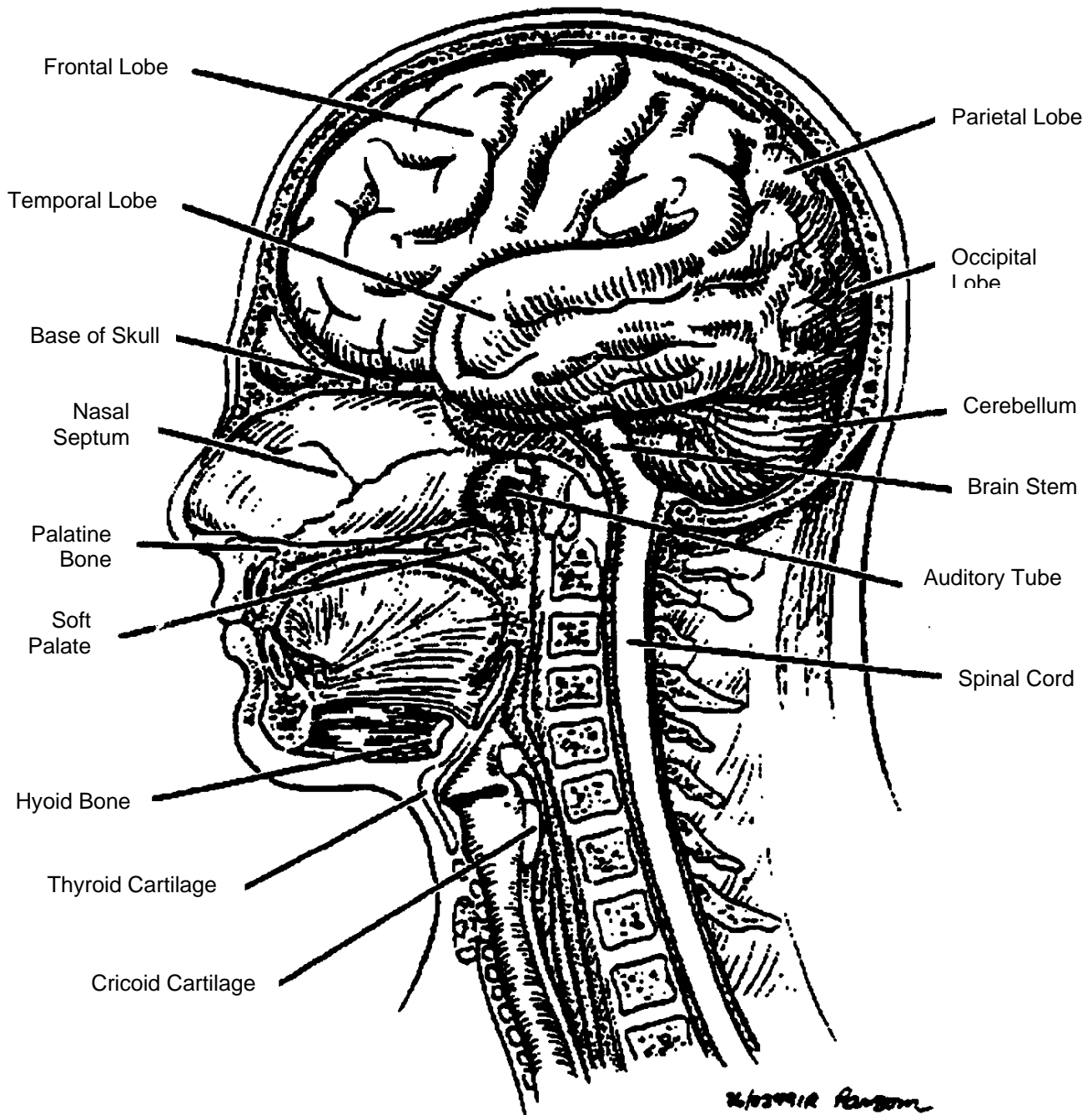
The **posterior portion of the frontal lobe** controls the initiation of voluntary movement. Dysfunction in this area may result in hemiplegia, spasticity or hemiparesis of the **opposite side** of the body and/or convulsive seizures.

Just posterior to the frontal lobe lies that part of the **parietal lobe** which represents the somatic sensory area. It is here that basic stimuli are felt and then redirected into surrounding sensory areas for more explicit interpretation. Lesions in this lobe result in disturbances in the sensation of touch.

The **temporal lobe** functions as the primary hearing centre and for the storage of memory patterns. Injury or illness to this area may result in receptive dysphasia (inability to understand the significance of the spoken word), visual hallucinations, visual defects and/or psychomotor seizures.

The posterior aspect of the occipital lobe is concerned with sight. Dysfunction within this lobe may manifest as blindness of the nasal half of one eye and the temporal half of the other and/or visual hallucination (with or without generalized convulsions).

FIGURE 2: SAGGITAL SECTION THROUGH THE HEAD (BRAIN INTACT)



THALAMUS

Situated below the inferior central portion of the cerebrum is the **thalamus**. The thalamus acts as a relay station which receives sensory impressions from lower regions in the body and projects them onto the cerebral cortex for interpretation. It is possible that certain types of pain may reach consciousness in this area as well.



Clinical vignette

Pain is a protective function and works by apprising the brain of almost any type of damaging process. This causes the appropriate stimuli. Pain receptors are activated only when body tissues are being stimulated – not only due to the initial damage but also from swelling, release of chemicals and other stimuli.

Damaged tissue immediately causes the release of substance called **bradykinin**, which stimulates pain nerve endings. Bradykinin also triggers the release of histamine. Histamine increases capillary permeability, allowing fluid, white blood cells and other chemicals into the damaged area, causing swelling and more pain.

Painful stimuli are received at exposed nerve endings throughout the periphery (skin) and the viscera. The impulses are carried to the spinal cord and then to the brain and interpretation. Examples of the stimuli damaging to tissues include:

- Trauma
- Ischemia
- Intense heat
- Extreme cold
- Chemical irritation

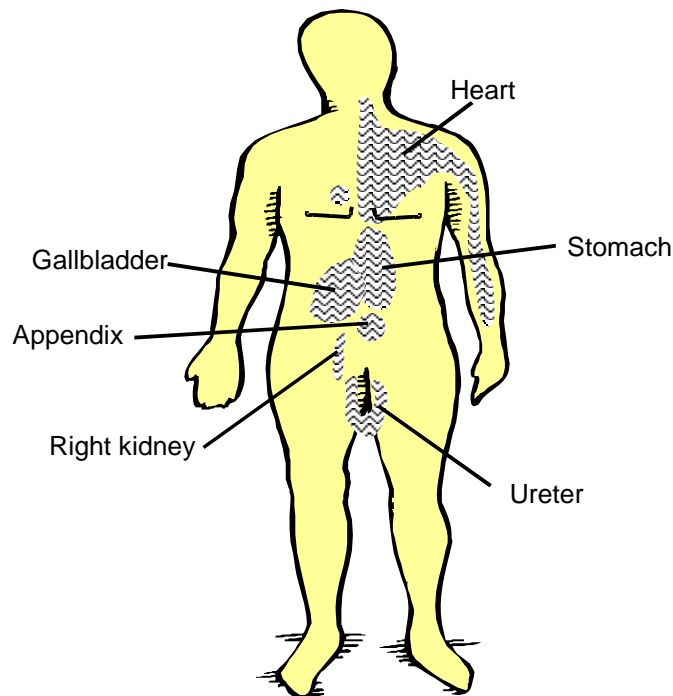
The stimuli for and the nature of the pain produced will vary to some degree for each tissue, for example:

- Skin – cutting or burning
- Digestive tract – distension or spasm
- Skeletal muscle – ischemia
- The heart – ischemia

Peripheral pain can be appropriately localized, via the cerebral cortex, to a specific body surface area. Visceral sensations (which may present as pain, a burning sensation or pressure) may be felt on a surface area of the body rather than within the organ itself. This is called **referred pain**. It may be referred to the surface immediately above the organ, or it may be felt in an area a considerable distance away from the originating organ.

The surface area to which visceral pain is referred usually corresponds to that portion of the body where embryonic development of the organ occurred, **e.g.** the heart originates in the embryonic neck as does the arm, therefore heart pain is frequently referred to the arm.

FIGURE 3: REFERRED PAIN



HYPOTHALAMUS

Lying beneath the thalamus is the **hypothalamus**. The hypothalamus has many functions. It is the main autonomic centre for the regulation of the activities of smooth muscle, cardiac muscle and endocrine glands. It also sends fibers to subordinate centres throughout the brain which regulate various automatic functions such as digestion, excretion and respiration. It is important as a control centre for hunger and thirst.

PITUITARY GLAND

The **pituitary gland**, which stores and/or releases several important hormones, is attached by a stalk to the inferior surface of the hypothalamus.

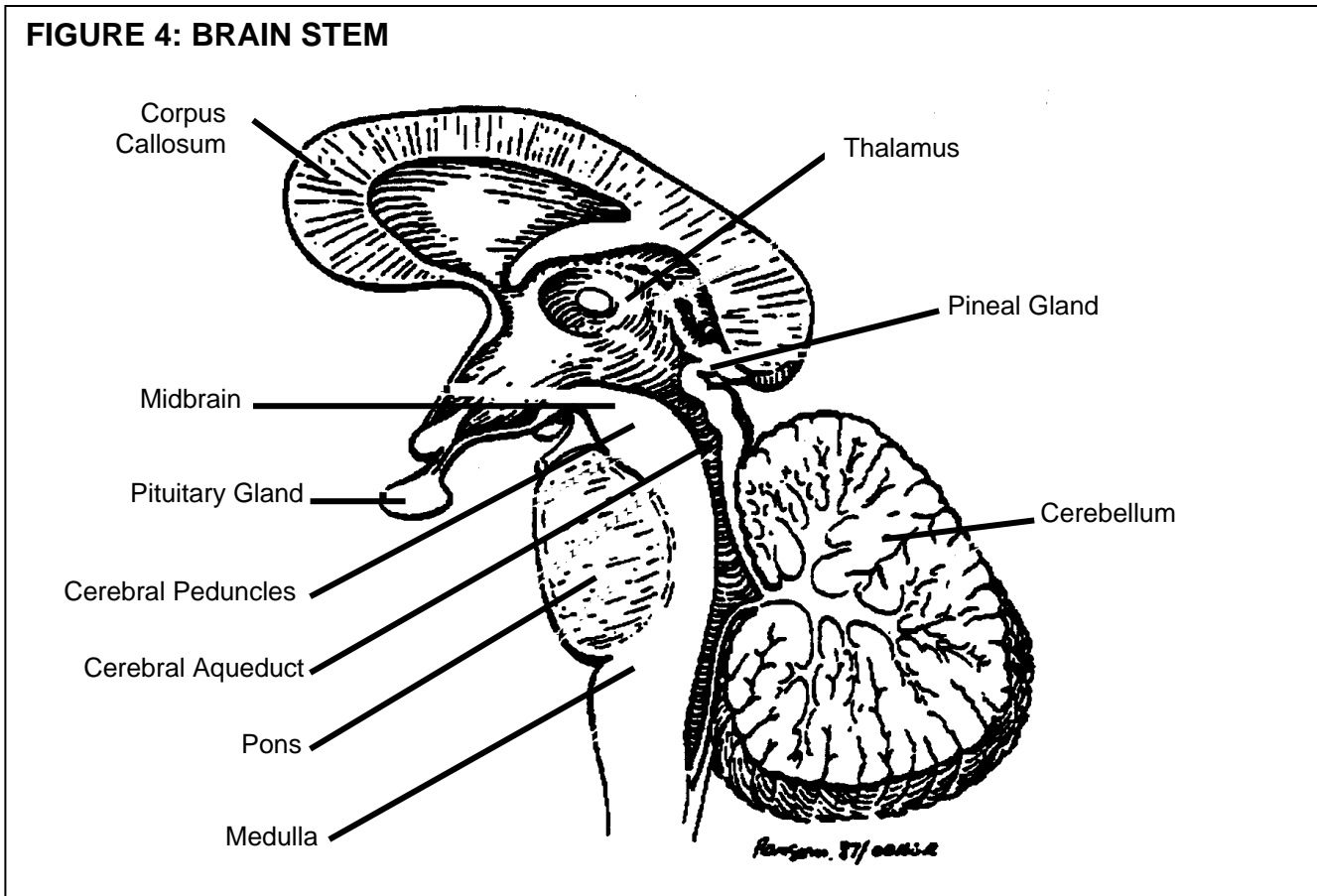
CEREBELLUM

The cerebellum is concerned with the control of posture and with fine muscle control. Illness or injury to this portion of the brain may result in headaches, vomiting and/or visual disturbances. These problems may involve neighbouring cranial nerves and/or the brain stem.

BRAIN STEM

Structurally, the brain stem is made of three divisions:

- o Midbrain
- o Pons
- o Medulla oblongata.



The midbrain lies just below the cerebrum. Structurally as well as functionally, it serves to connect the cerebrum to the lower brain centers and the spinal cord. It is an important site of visual and auditory reflex activity, and is the origin for cranial nerves III and IV (pupillary reflexes and eye movements).

Lying inferior to the midbrain and superior to the medulla oblongata is the **pons** which functions as a conduction network between the spinal cord and brain. It contains the nuclei of cranial nerves V through VIII.

The **medulla oblongata** is also a conduction pathway between the spinal cord and brain. This area is formed by an enlargement of the cord as it enters the cranial cavity through the foramen magnum. The medulla oblongata contains the nuclei for the cranial nerves VIII through XII. It is a centre for the reflexes of vomiting, coughing and hiccuping.

The most important function of the medulla oblongata is that it serves as the control centre for vital visceral activities including:

- Cardiac vital centre (controls the heart rate)
- Vasomotor vital centre (sends impulses to the smooth muscles in the walls of blood vessels causing them to constrict, with a subsequent rise in blood pressure)
- Respiratory vital centre (functions with the pons to regulate the rate, depth and rhythmicity of breathing).

Illness or injury affecting the medulla oblongata can result in death due to the compromise of vital control centers.

Scattered throughout the entire brain stem, but concentrated in the medulla oblongata, is a collection of large and small-interconnected neurons known as the **reticular formation**. This net-like structure of gray and white matter is believed essential for the cortical activities associated with initiating and maintaining wakefulness. As such, it is often referred to as the **Reticular Activating System (RAS)**.

Very little is known about the neural mechanisms that produce the cerebral function of consciousness. Self-awareness and awareness of one's environment may define the state of consciousness. One fact is clear; the excitation of cortical neurons by impulses conducted to them by the RAS is necessary for consciousness. The cerebral cortex cannot activate itself. Without continuous stimulation an individual will remain unconscious and will not be able to be aroused.

As well as being crucial for maintaining consciousness, the RAS is considered the arousal or alerting system for the cerebral cortex. Pain, loud verbal stimuli and/or movement can cause an arousal reaction, **e.g.** immediate activation of the RAS. This is the means by which sensory stimuli awaken us from sleep.

Drugs that act directly on the RAS will affect the level of consciousness, **e.g.** barbiturates depress the RAS while amphetamines are thought to stimulate this system.

VENTRICLES OF THE BRAIN

The ventricles are four fluid-filled interconnected cavities located within the cerebral hemispheres and brain stem. The fluid circulating between the ventricles and through the **subarachnoid space** of the skull and spinal column is called **cerebrospinal fluid (CSF)**. This fluid is secreted into the ventricles, circulates and is then reabsorbed. The delicately balanced volume of CSF primarily consists of water containing glucose, sodium chloride and protein. The main function of CSF is to act as a fluid cushion to protect the delicate brain and spinal cord tissue, maintaining a constant environment for these vital structures.

MENINGES

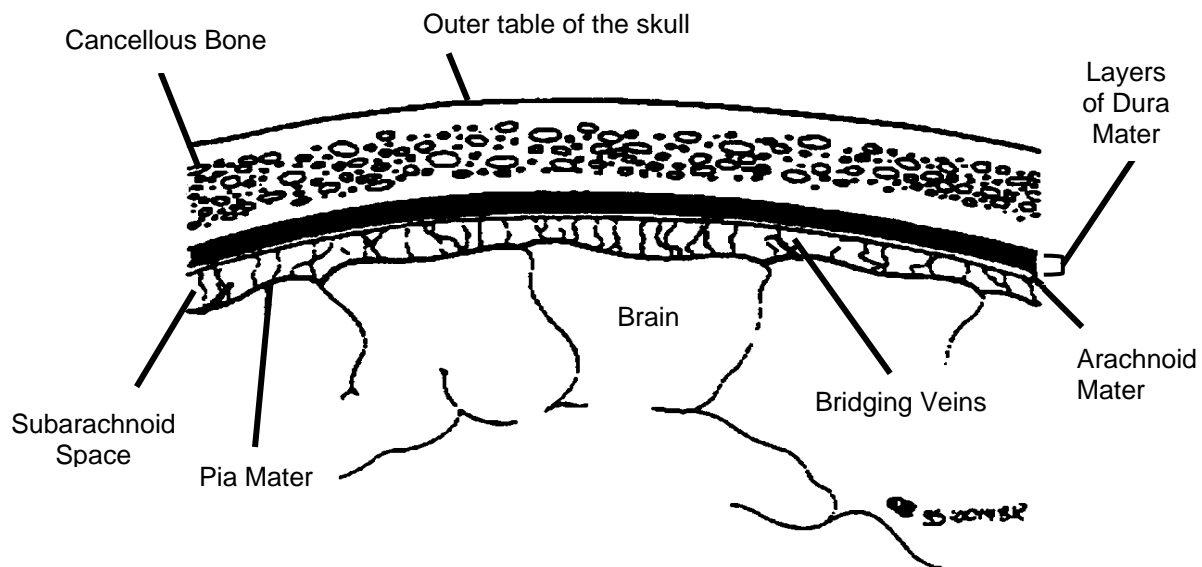
The brain and spinal cord possess three complete membranes coverings known as meninges. From outermost to innermost, these are the **dura mater**, the **arachnoid mater** and the **pia mater**.

In the cranial cavity, the avascular dura mater comprises not only the tough fibrous outermost covering for the brain, but also the lining membrane (periosreum) on the inner surface of the skull. There is normally no space between these two layers.

The **arachnoid mater** is a very thin, delicate, avascular membrane which lines and completely adheres to the inner surface of the dura mater. Between the arachnoid mater and the underlying pia mater is the **subarachnoid space**, containing **cerebrospinal fluid**.

The **pia mater** is a transparent, delicate membrane which completely adheres to the outer surface of the brain and spinal cord like a “skin”. The pia mater contains blood vessels and is therefore a nutritive layer as well.

FIGURE 5: SCHEMATIC DIAGRAM OF THE MENINGES



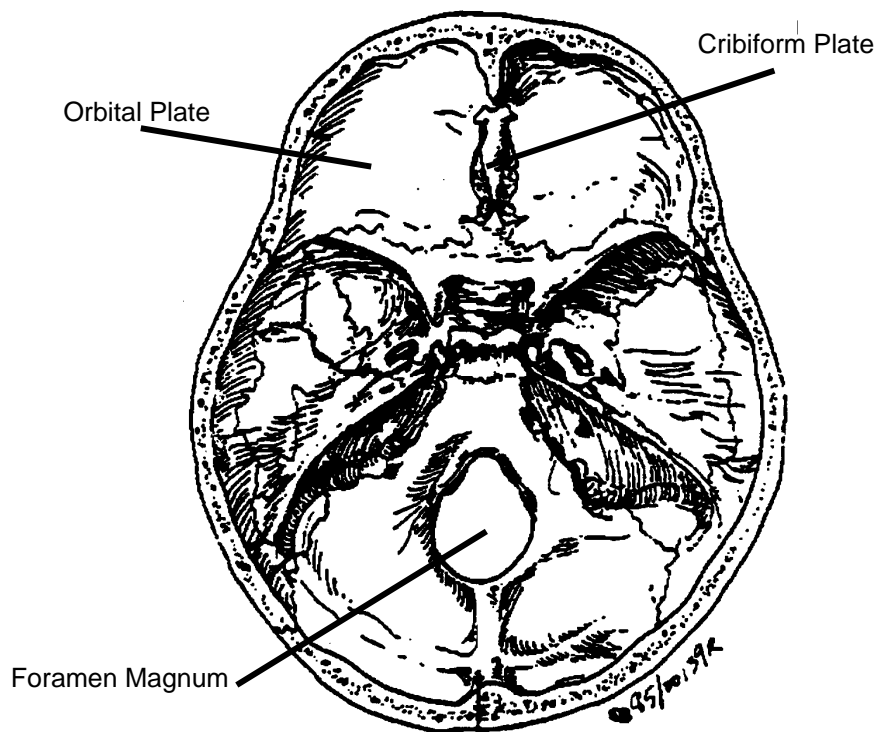
THE SKULL

Underneath the three layers comprising the scalp lies the skull, a cranial vault which is especially thin in the temporal regions. The **cranium** is a fusion of many smaller bones joined at **suture lines**.

The base of the skull is irregular and internally rough. This term actually refers to the floor of the skull, as seen from above. The base is comprised of the bones behind the nose and above the roof of the mouth, namely the ethmoid and sphenoid.

In the event of a skull fracture, the type and extent of this injury will vary with the age of the patient and the nature of the injury, **i.e.** mechanical agent and amount of force.

FIGURE 6: BASE OF SKULL



BLOOD SUPPLY TO THE BRAIN

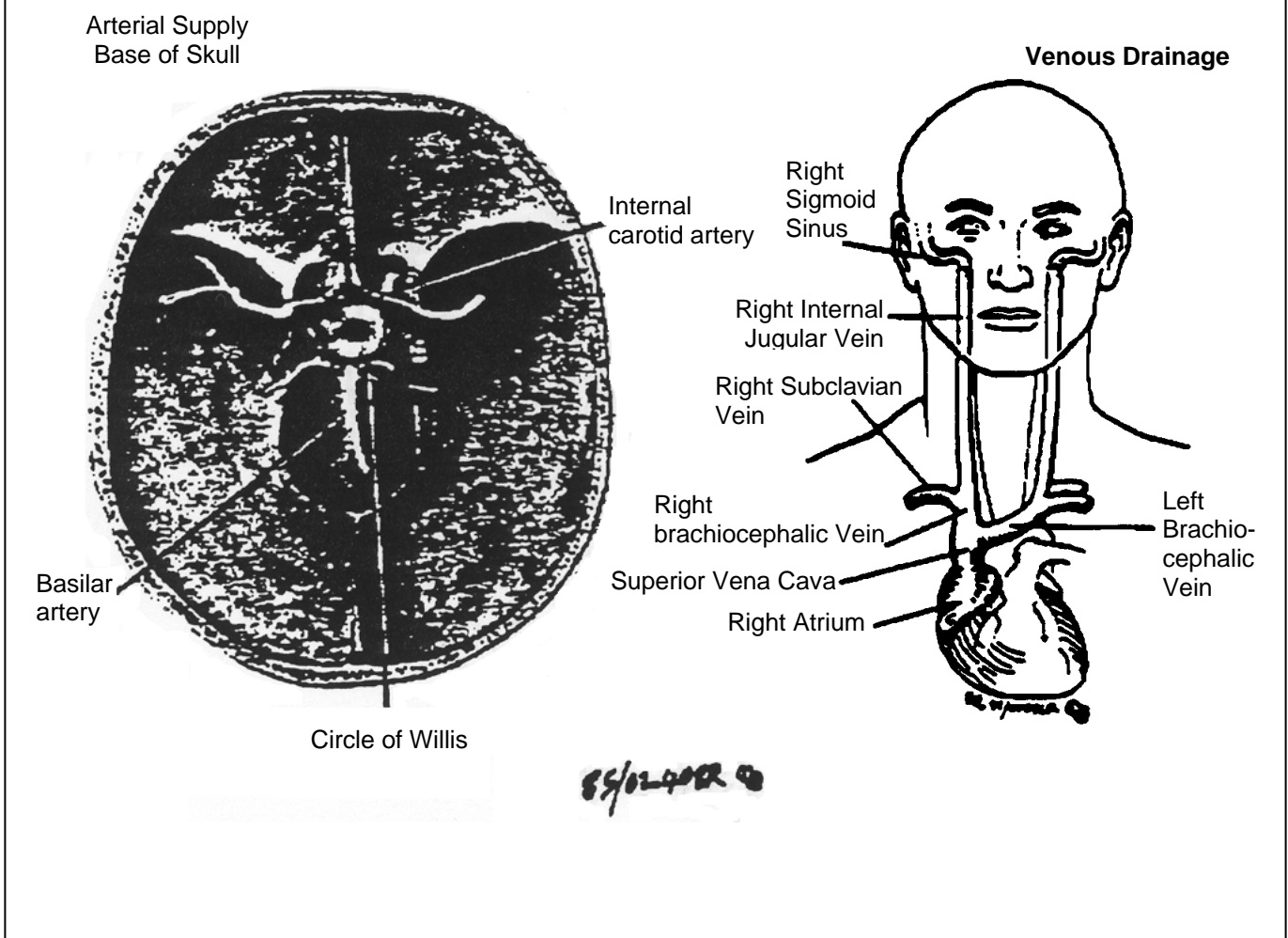
It is impossible to over emphasize the importance of an uninterrupted blood supply to the brain. The brain receives about 16 % of the total cardiac output and consumes about 20 per cent of the oxygen used by the whole body. An abrupt cessation of oxygen carrying blood to the brain may lead to an unconscious state in several seconds. Brain death follows in several minutes from the initial cessation of oxygen. The amount of time this actually takes depends on predisposing medical and environmental factors. The brain stores approximately a 10

second supply of oxygen. This means that metabolic failure is almost instant with cerebral hypoxia.

Glucose is another life-sustaining component found in blood. The lack of this substance in the blood, e.g. hypoglycemia, results in diminished cellular metabolism which especially affects the brain. If hypoglycemia is prolonged, cell death slowly occurs – eventually causing brain death.

The superficial (external) and deep (internal) cerebral veins drain venous blood from the cerebrum. The cerebral veins empty into the dura sinuses, which are channels that lie between the two layers of dura mater. Venous blood drains into its respective **internal jugular vein** (right and left). All venous blood of the brain empties into the two internal jugular veins.

FIGURE 7: CIRCULATION OF BLOOD IN THE BRAIN

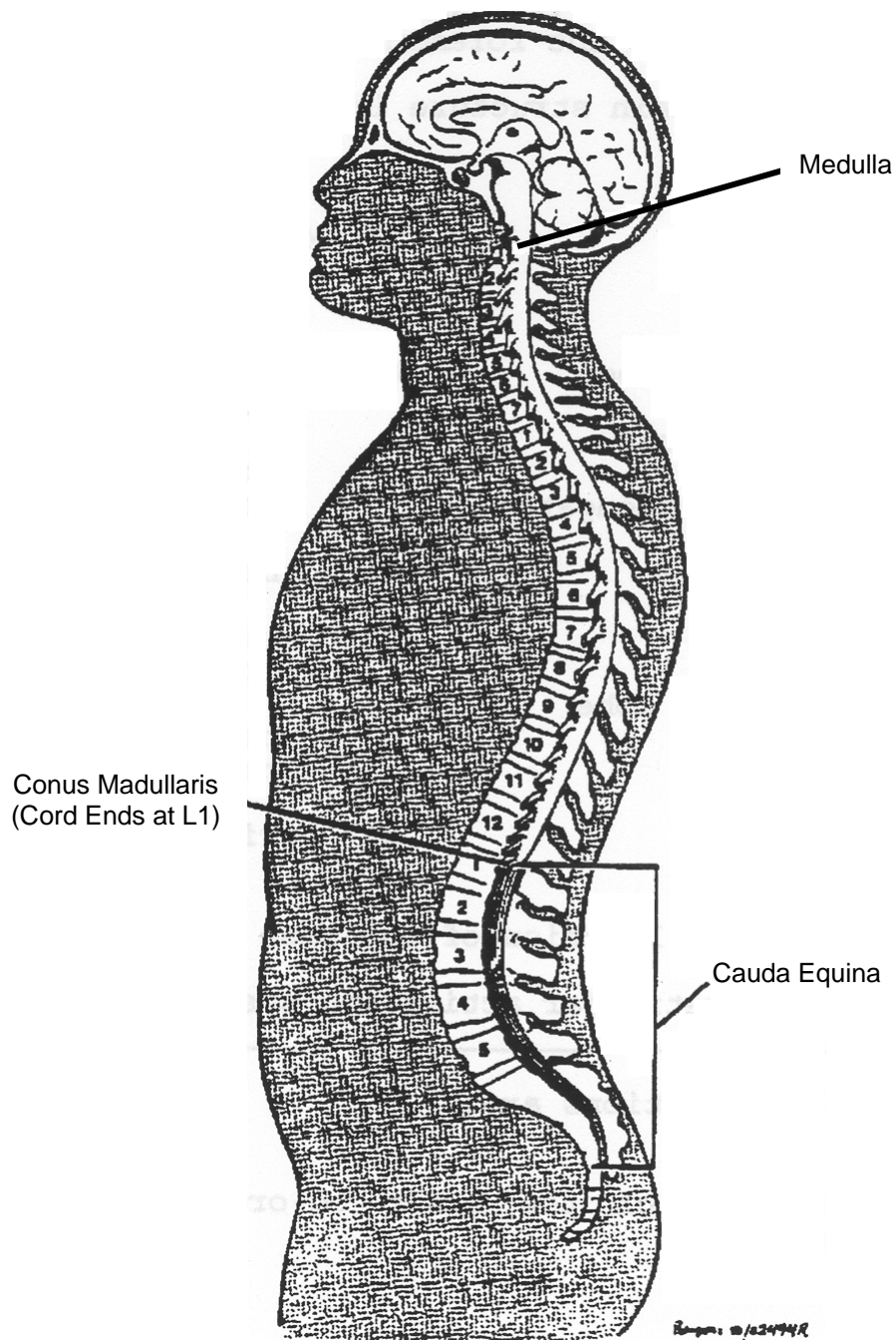


THE SPINAL CORD

The medulla oblongata continues outside the skull as the **spinal cord**, a rod of nervous tissue approximately 45 cm in length in the adult. The spinal cord terminates in the lower back (at L₁ in the adult) as the **conus medullaris** (Figure 8).

The coverings or meninges of the spinal cord are the same as those around the brain and are continuous with the meninges around the brain.

FIGURE 8: SPINAL CORD



**ADVANCED LIFE SUPPORT
PRECOURSE
THE NERVOUS SYSTEM**

SELF-ASSESSMENT: CENTRAL NERVOUS SYSTEM

Marks

- [1] 1. Which part of the brain extends from the cerebral hemisphere to the foramen magnum?

- [7] 2. Match the brain structure in Column A with its function in Column B.

COLUMN A

1. Thalamus
2. Temporal lobe
3. Hypothalamus
4. Medulla oblongata
5. Cerebellum
6. Cerebrum
7. Occipital lobe

COLUMN B

- a) concerned with sight
- b) contains cardiac vital center
- c) center for static and dynamic equilibrium
- d) the main autonomic center
- e) relay station for sensory impressions
- f) the intellectual center of the brain
- g) primary hearing center

- [2] 3. Describe the location of the base of the skull.

[1] 4. a) The reticular activating system is located _____.
b) Its two functions are:

[1] 5. Which part of the brain co-ordinates muscle tone and movement?

[2] 6. The pituitary gland is located on the undersurface of the (a) _____.
It is protected inferiorly by (b) _____.

[2] 7. There are (a) _____ cerebral hemispheres
connected by a structure called (b _____).

[2] 8. Where is CSF found? What is its main function.

[1] 9. a) The coverings of the brain and spinal cord are collectively called _____.

[3] b) From the skull proceeding to the brain, name these covering layers.

[1] c) Between which two layers is the subarachnoid space located?

[1] d) What is found in this space?

[2] 10. Name the four main lobes of each cerebral hemisphere.

[2] 11. The spinal cord extends from the (a) _____ to the lower level of the first lumbar vertebra. The termination of the spinal cord is known as the (b) _____.

[1] 12. All venous blood from the brain drains into the _____.

[1] 13. The brain receives over 50% of the total cardiac output. (True or False).

30 TOTAL

**ADVANCED LIFE SUPPORT
PRECOURSE
THE NERVOUS SYSTEM**

SELF-ASSESSMENT ANSWERS: CENTRAL NERVOUS SYSTEM

1. Brain stem
2.
 1. e
 2. g
 3. d
 4. b
 5. c
 6. f
 7. a
3. The flow, as seen from above, comprised of the bones behind the nose and above the roof of the mouth.
4.
 - a) Throughout the brain stem, but primarily in the medulla oblongata.
 - b) - control of wakefulness and consciousness
- responsible for the protective mechanism of the arousal reaction in response to certain stimuli.
5. Cerebellum
6.
 - a) Hypothalamus
 - b) Bone (skull)
7.
 - a) Two
 - b) The corpus callosum
8. CSF is found in the ventricles of the brain, in subarachnoid space around the brain and in the spinal cord. The main function of CSF is protection.
9.
 - a) Meninges
 - b) Dura mater
Arachnoid mater
Pia mater
 - c) Arachnoid mater and pia mater
 - d) Cerebrospinal fluid (CSF)

10. Frontal, temporal, parietal, occipital
11. a) Foramen magnum
b) Conus medullaris
12. Internal jugular vein
13. False (the brain receives a large % of the cardiac output = 16% but not 50%).

**ADVANCED LIFE SUPPORT
PRECOURSE
NERVOUS SYSTEM**

PERIPHERAL NERVOUS SYSTEM

Neurons (nerve cells) are comprised of a cell body (containing the nucleus) and an extension called the axon which terminates either at a synapse (junction with another nerve fibre) or an end plate in a muscle or organ.

Peripheral nerves consist mainly of long axons running the whole length of the nerve. The cell bodies of motor nerves are located inside the spinal cord; while those of sensory nerves are just outside the spinal cord in groups called ganglia (singular-ganglion). Autonomic (involuntary) nerves are connected together by a chain of ganglia lying adjacent to the spinal column in the thoracic and abdominal cavities.

Because of differences in function, the peripheral nervous system is classified as either:

- o Somatic (voluntary) or,
- o Autonomic (involuntary)

SOMATIC NERVOUS SYSTEM

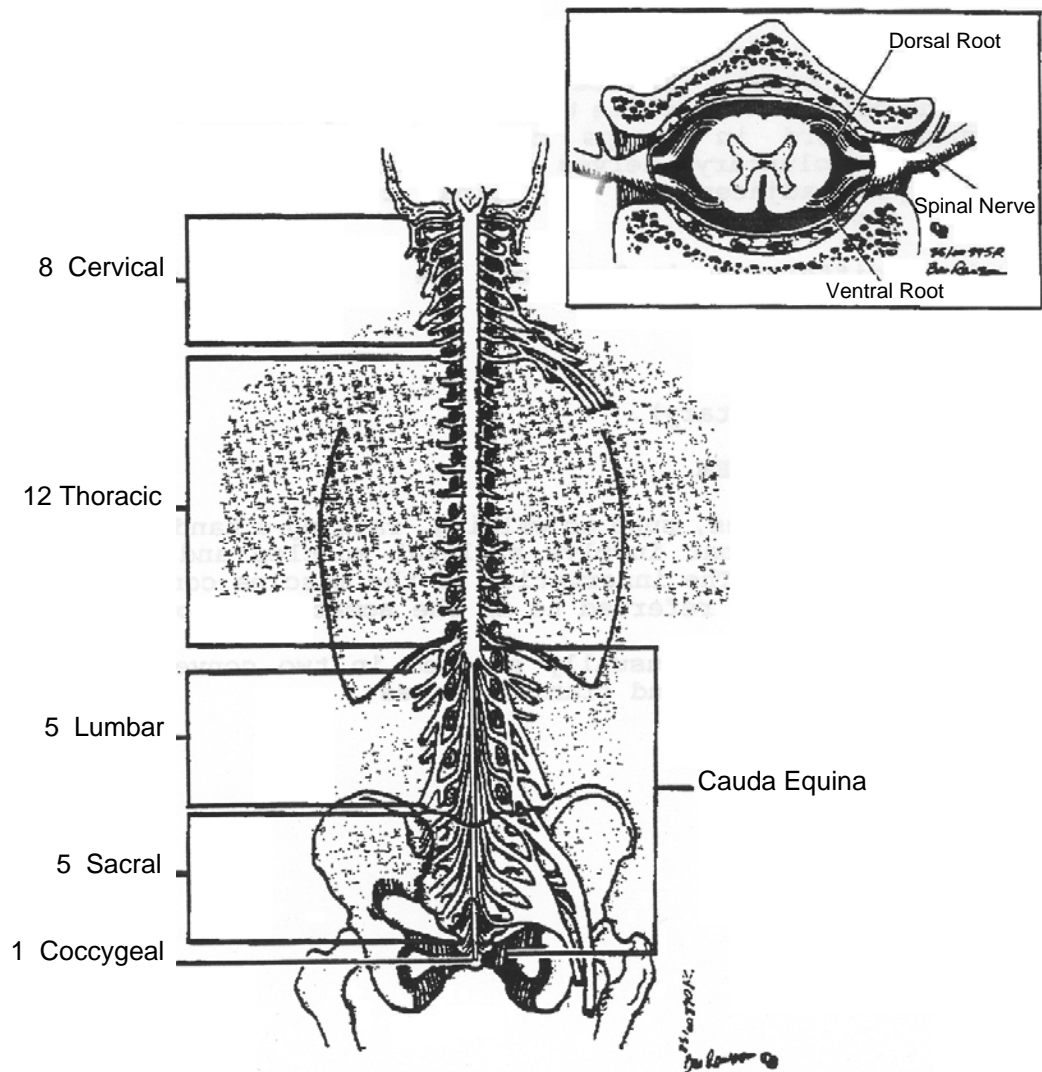
Many of our activities, such as walking, raising a hand or opening our mouth are actions that involve skeletal muscles and are under our conscious control. The innervation of the muscles controlling these voluntary actions is referred to as the **somatic nervous system**.

The somatic nerves are usually studied in two convenient anatomic groups: spinal nerves and cranial nerves.

SPINAL NERVES

Arising from the lateral aspect of the spinal cord are nerves that transmit impulses to and from skeletal muscle. There are 31 pairs of such nerves known as spinal nerves which correspond to the segments of the spinal cord. (8 cervical, 12 thoracic, 5 lumbar, 5 sacral, 1 coccygeal). These fibres however enter and exit the spinal column between L₁ and L₂.

FIGURE 9: SPINAL NERVES



When the spinal cord is cut transversely (across), the tissue will show two areas of different colour. There is a central H-shaped dark area and an outer white area. The dark or gray area is chiefly composed of nerve cell bodies, while the white matter is chiefly made up of nerve fibres (axons).

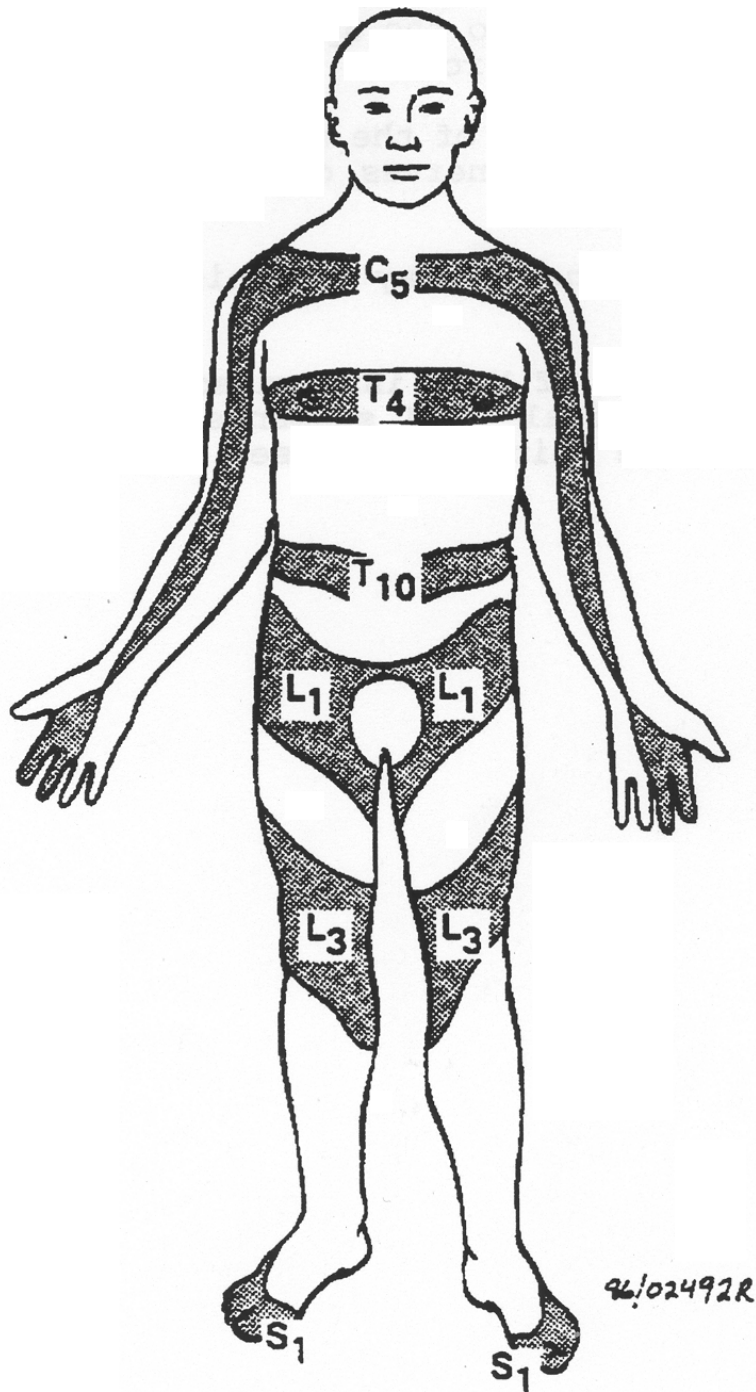
Attached to the dorsal aspect of the spinal cord, are the **sensory** roots. Nerves bring stimuli to the spinal cord from skeletal muscle through the sensory or dorsal roots.

Attached to the ventral aspect of the spinal cord, are the **motor** roots of the spinal nerves. These nerves carry impulse from the spinal cord to the skeletal muscles.

The spinal cord provides the two-way communication system between the brain and body parts.

Dermatomes indicate areas of body innervated by specific spinal cord segments. Note that the spinal cord segments do not correspond with vertebral bodies and the spinous processes correspond with neither.

FIGURE 10: DERMATOMES

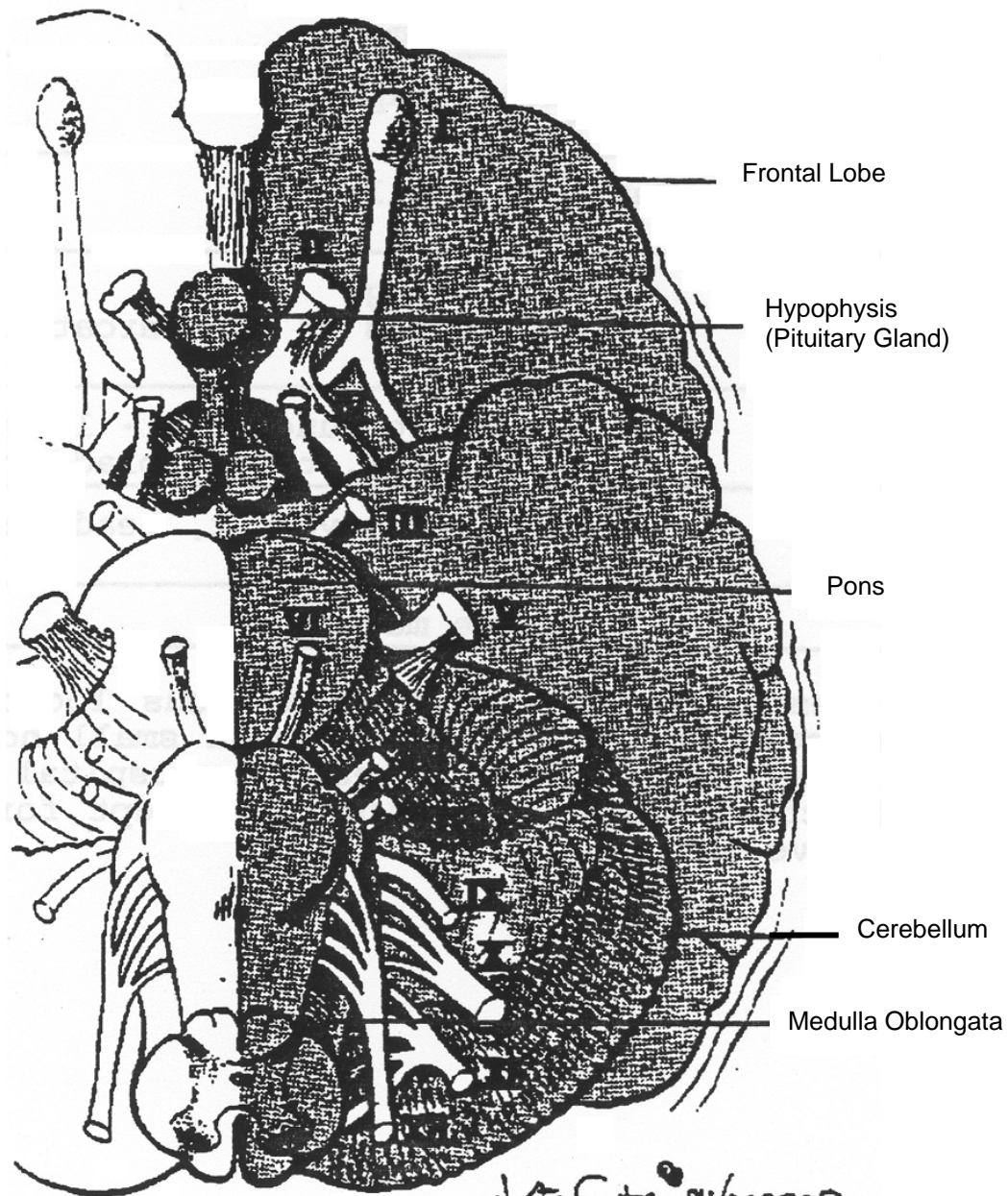


CRANIAL NERVES

There are 12 pairs of nerves that arise from the base (bottom) of the brain. Because these nerves arise from within the skull, they are referred to as cranial nerves.

The cranial nerves are important for such functions as sight, hearing, vision, heart action, digestion and respiration. You will note that some of these nerves more appropriately belong to the autonomic system since they either partially or exclusively control involuntary functions, e.g. III, VII, IX, X.

FIGURE 11: BASE OF BRAIN SHOWING ORIGIN CRANIAL NERVES I – XII



**TABLE 1
IDENTIFYING CRANIAL NERVES**

NERVE	FUNCTION(S)
I. Olfactory	Smell
II. Optic	Vision
III. Oculomotor	Equality and reaction of pupils. Eye movement, eyelid elevation, pupil constriction, consensual reaction
IV. Trochlear	Eye movement
V. Trigeminal	Chewing Sensations of the face (facial anaesthesia) Corneal reflex
VI. Abducens	Eye movement
VII. Facial	Facial expressions (look for unequal facial Expression – e.g. stroke. Inability to close one eye) Taste
VIII. Acoustic (cochlear, hearing, equilibrium vestibular)	“Ringing in the ears” (tinitis) Nystagmus
XI. Glosso-pharyngeal	Swallowing Sensations of the throat and tonsils Pharyngeal/gag reflex (sensory)
X. Vagus	Autonomic functions – lungs, heart, G.I. tract, bladder Gag reflex response (motor)
XI. Spinal	Shoulder movement, head accessory rotation
XII. Hypoglossal	Tongue movement

The 12 cranial nerves leave the brain in various locations, pass through the subarachnoid space and then through small holes in the skull to arrive at their destination sites. Prehospital evaluation of cranial nerve function has a low priority, except for pupillary response (cranial nerve III).

AUTONOMIC NERVOUS SYSTEM

There are many tissues and organs in our body that we cannot consciously or voluntarily control. Such activities as heart contractions, digestive processes, dilation and constriction of blood vessels and pupil size are all done automatically or involuntarily. The innervation of these muscles and glands is by the **autonomic nervous system**.

Anatomically, the parasympathetic (or craniosacral) division of the autonomic nervous system accompanies cranial nerves from the brain and from spinal nerves at the lower end of the spinal cord (Figure 12).

All sympathetic (or thoracolumbar) nerves arise with spinal nerve along the most of the spinal cord. They are connected by a chain of ganglia running parallel to the spinal column.

In general the sympathetic and parasympathetic divisions of the autonomic nervous system have opposing actions. For example, the stimulation of the heart by the sympathetic division will increase the heart rate, while stimulation by the parasympathetic division will slow the heart.

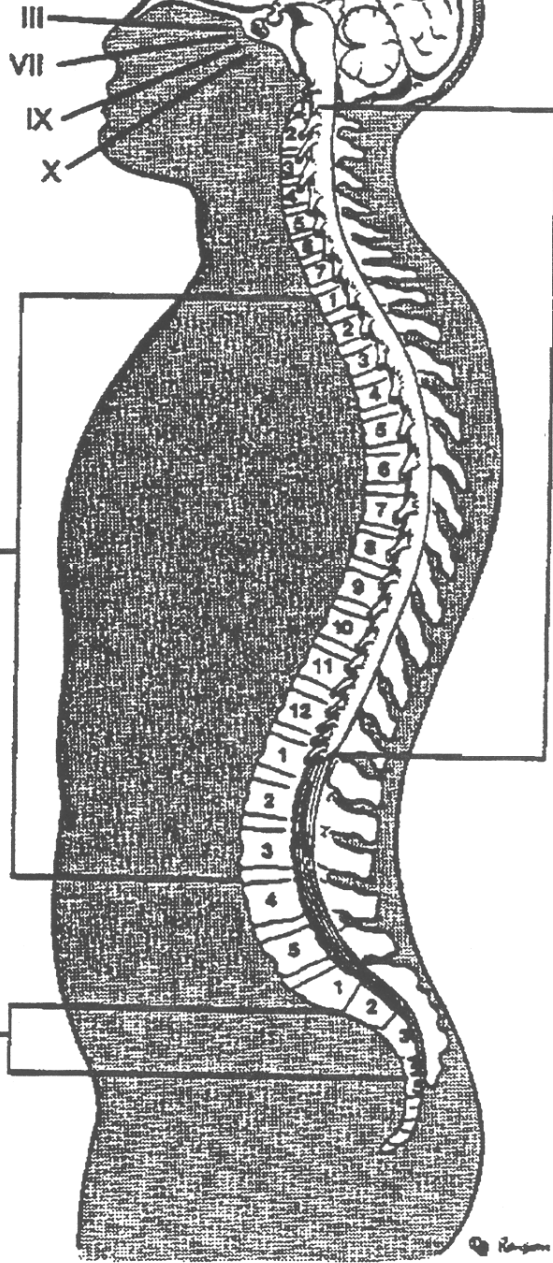
The sympathetic system, (SNS) prepares the body for stressful situations and emergencies, requiring fast action and great exertion. It increases the heart rate and respiration, dilates pupils, curtails digestion, and makes you hair “stand on end”.

The parasympathetic system, (PNS) restores the body to normal conditions when the emergency has diminished. The system promotes digestion, slows the heart rate and breathing to normal and causes the pupils to return to normal size.

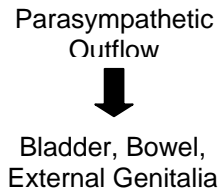
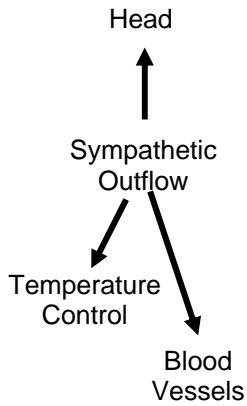
FIGURE 12: INNERVATION OF ORGANS BY THE SYMPATHETIC AND PARASYMPATHETIC DIVISIONS OF THE AUTONOMIC NERVOUS SYSTEM

AUTONOMIC

Parasympathetic Outflow (with cranial nerves)



Motor & Sensory Function (Somatic Nervous System)



An important function of the sympathetic nervous system is the control of blood vessels. Most of these vessels are constricted by SNS stimulation of the smooth muscle layer within the vessel. However, in order to provide more blood flow under stressful conditions to the areas they serve, the coronary vessels and skeletal muscle vessels are dilated. By controlling peripheral blood vessel diameter, the SNS is capable of regulating both cardiac output and arterial pressure. (Constriction of veins and venous reservoirs increases cardiac output; constriction of arterioles increases peripheral resistance, which elevates arterial blood pressure.)

TABLE 2
AUTONOMIC EFFECTS ON VARIOUS ORGANS OF THE BODY

ORGANS	EFFECT OF SNS STIMULATION	EFFECT OF PNS STIMULATION
EYE	Dilated pupil	Contracted pupil
SWEAT GLANDS	Copious sweating	None
HEART	Increased activity Vasodilated coronaries	Decreased activity Constricted coronaries
SYSTEMIC BLOOD VESSELS		
❖ Abdominal	Constricted	No action
❖ Muscle	Dilated	No action
❖ Skin	Constricted or dilated	No action
LUNGS	Dilated bronchi	Constricted bronchi
GUT	Decreased peristalsis	Increased peristalsis

Other autonomic effects from SNS stimulation where the PNS has no effect include:

- Increased glucose released to blood from liver
- Decreased urinary output from kidneys
- 50% increase in basal metabolism
- Increased adrenal cortical secretion
- Increased mental activity.

**ADVANCED LIFE SUPPORT
PRECOURSE
NERVOUS SYSTEM**

SELF-ASSESSMENT: PERIPHERAL NERVOUS SYSTEM

Marks

[1] 1. The innervation to the muscles involved in such activities as running and throwing a baseball is known as the _____ nervous system.

[2] 2. What is the autonomic nervous system?

[1] 3. What is the effect on the heart when stimulated by the sympathetic division of the autonomic nervous system?

[5] 4. For the following body actions indicated whether the sympathetic or parasympathetic division is predominant.

a) Dilation of pupils _____

b) Digestive processes slowed _____

c) Increased ventilation _____

d) Body is prepared for any emergency situation _____

e) Digestive processes restored to normal _____

[1] 5. Name the cranial nerve that controls the pupillary reflex.

[1] 6. The main function of the spinal cord is: _____.

10 TOTAL

**ADVANCED LIFE SUPPORT
PRECOURSE
THE NERVOUS SYSTEM**

SELF-ASSESSMENT ANSWERS: PERIPHERAL NERVOUS SYSTEM

1. Somatic
2. Autonomic nervous system is the innervation of organs and glands that function automatically.
3. Increases heart rate.
4.
 - a) Sympathetic
 - b) Sympathetic
 - c) Sympathetic
 - d) Sympathetic
 - e) Parasympathetic.
5. Third or oculomotor.
6. Pathway for conduction of nerve impulses to and from the brain.

**ADVANCED LIFE SUPPORT
PRECOURSE
NERVOUS SYSTEM**

TRANSMISSION OF NERVE IMPULSES

FUNCTIONS OF NERVOUS TISSUE

All activities that we are involved with every day of our lives are controlled by the nervous system.

We have all experienced one of the joys of life, basking in the sunlight of an early summer morning. Who would not count as one of the great things in life, the warmth of the sunlight, a gentle breeze rustling through the trees, the singing of the birds or the sight and smell of flowers as we marvel at the world around us.

From this beautiful, but simple experience, we can identify the chief functions of the nervous system.

1. Transmission of the Nerve Impulse

The various sensations that have been briefly delineated in our early morning walk are eventually **transmitted** to the brain from the eyes, ears, nose, and skin. Within the brain, the information is analyzed.

2. Interpretation

When the impulses from our various sense organs (and all other areas of the body) are received by the brain, such impulses or messages are sorted out or **interpreted**. Finally, information received by the brain may be stored for future reference.

3. Storage

The various pleasant sensations associated with a warm day may be recalled and experienced again on a later cold winter day.

Storage of information (memory) is such a complicated function of the brain, it is entirely likely there are various areas designated for this function. Events that occurred yesterday may be stored in one area of the brain, and as time passes, moved to another brain site for long term memory.

All living organisms possess the ability to **transmit** nerve impulses. However, the functions of **interpretation** and **storage** are characteristic of higher forms of life, as exemplified by man.

How Is The “Message” Carried?

The “message” refers to the impulses (stimuli) that are relayed (transmitted) **from** tissues and organs that comprise the body, to the spinal cord and brain. It is also apparent that messages are sent from the brain and spinal cord to all the components that make up the human body.

Such information is carried by **neurons**, the functional units of nervous tissue. Neurons are found throughout the body. It has been estimated that the number of neurons within the brain alone may exceed twenty billion.

Functionally, neurons may be divided into two main types:

1. Sensory (Afferent) Neurons

The sensory neurons are concerned with conveying impulses to the brain and spinal cord (central nervous system) from tissues and organs any place in the body, **e.g.** fingers, toes.

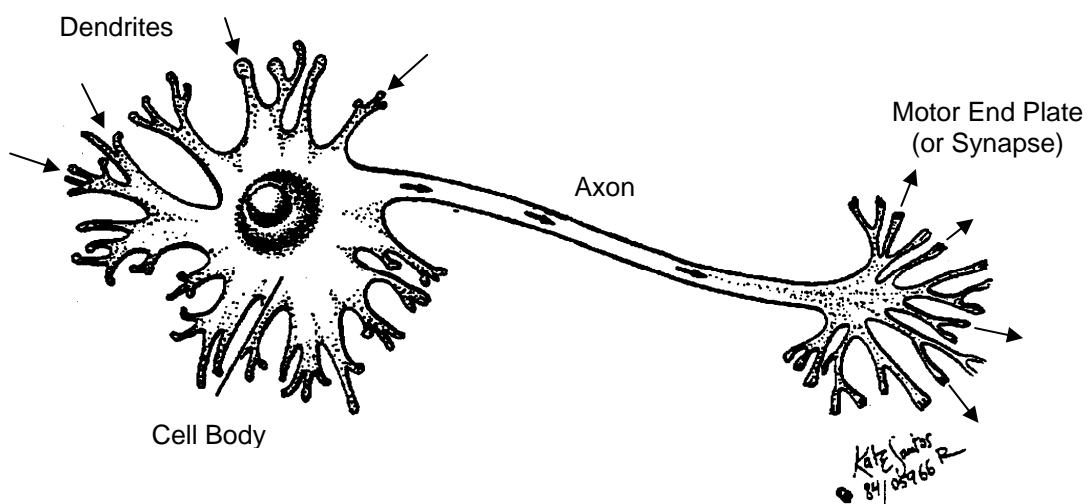
2. Motor (Efferent) Neurons

The motor neurons are concerned with carrying impulses away from the brain and spinal cord to all structures in the body.

There are, in addition to sensory and motor neurons, neurons that connect or join motor and sensory neurons. These are exclusive to the brain and spinal cord, and are referred to as **internuncial** neurons or interneurons.

Although sensory and motor neurons are functionally different, they are similar in structure. Impulses are carried by both in the same manner. The impulse travels from the dendrite end of the neuron to the motor end plate (or synapse) of the neuron.

FIGURE 13: DIRECTION OF NERVE IMPULSE WITHIN A NEURON



Efferent fiber arrangement is slightly different in each of the peripheral nervous systems.

The **somatic** (cranial and spinal nerves) efferent pathway to the skin and skeletal muscles consists of only one neuron. In contrast, in the autonomic system, impulses to visceral structures consists of one neuron from the brainstem or spinal column to a ganglion outside the spinal cord (**preganglionic neuron**), and one from the ganglion to the end organ known as the visceral effector.

Naturally, this fiber is named **postganglionic neuron**. This concept assumes clinical importance when discussing neurotransmitters.

EXCITABILITY AND CONDUCTIVITY

Nervous tissue has the property of **excitability**, which means it has the ability to respond to a change in the environment. When stimulated, nervous tissue also has the property of conductivity, which is the ability to **transmit** nerve impulses to the central nervous system. “Messages” or “orders” are then conveyed back to the various effectors to make adjustments.

Nerve impulses are then initiated by receptors in tissues, in response to changes in the internal and external environments.

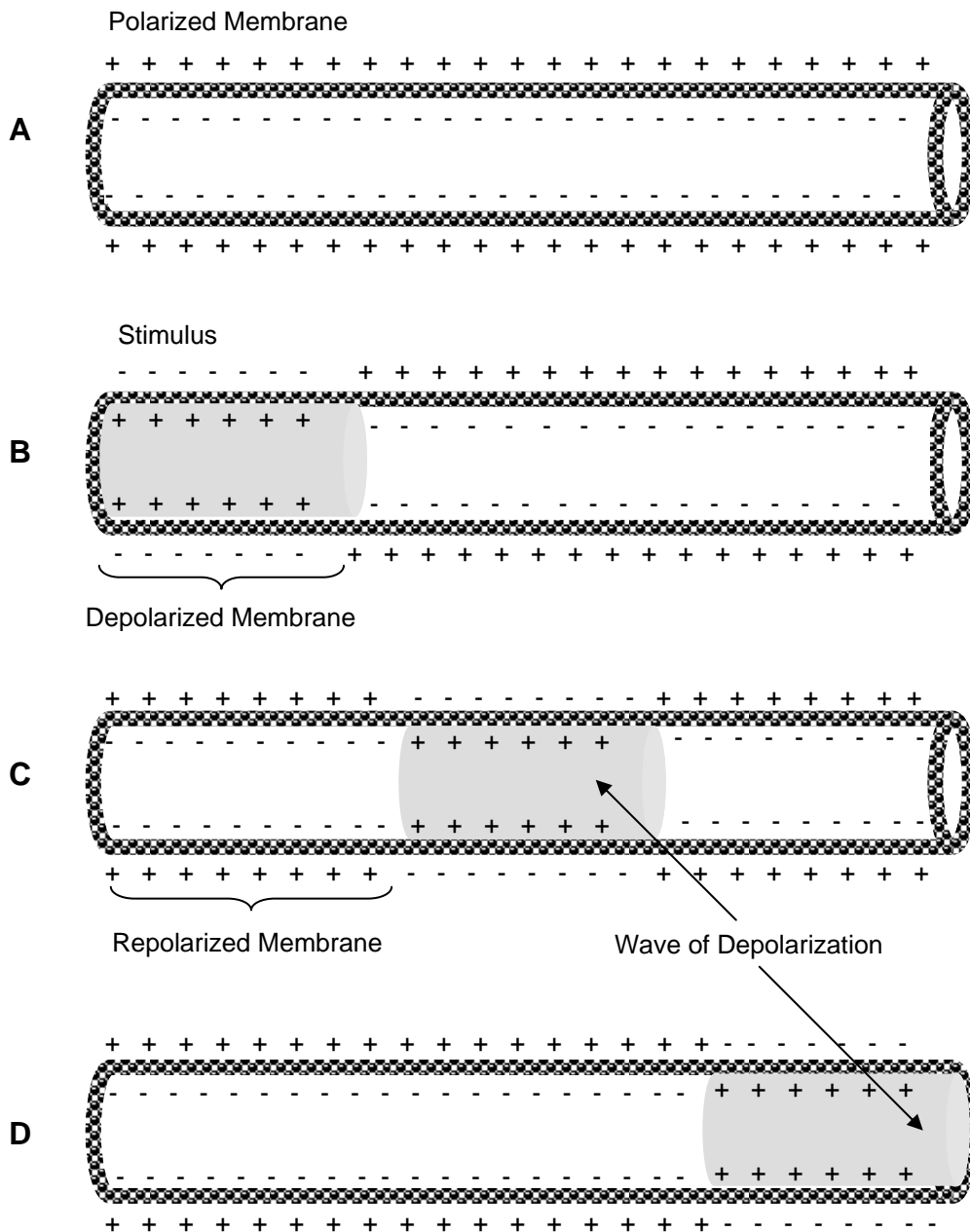
Nervous tissue has the ability to respond to a stimulus. This response is manifested by the transmission of the nerve impulses and is a complex action. The transmission of electrical impulses (illustrated in Figure 14) along the axon membrane can be briefly explained as follows:

- o A **resting neuron** is in a non-conducting state (Figure 14A). The semi-permeable membrane is polarized through the active transport of Na⁺ (sodium pump). When the outside of the semi-permeable membrane is more positive, relative to the inside, it is said to have a resting **potential**.
- o When a stimulus is applied, a **momentary depolarization** occurs (Figure 14B) resulting in a sudden reversal of the passage of Na⁺ through the semi-permeable membrane. Sodium ions now quickly enter the neuron from the extracellular fluid area. (Some potassium ions from the intracellular fluid within the neuron diffuse out at the same time.) Although the sodium and potassium ions are both cations (positively charged) the differing amounts intracellularly and extracellularly create a **relative** difference in the electrical charges inside and outside the semi-permeable membrane of the neuron.
- o The reversal of polarization results in an action potential which allows the stimulus to be carried along the nerve fiber (Figure 14C). Once an action potential is reached within a neuron, **impulse conduction** will occur along the full length of the fiber (all or none principle).

- o The **action potential** continues to travel along the membrane while immediately “behind” it occurs the recovery of the resting potential and a return towards a relative positive charge outside of the semi-permeable membrane (Figure 14D).

Once repolarization is achieved, an impulse may again be initiated and carried.

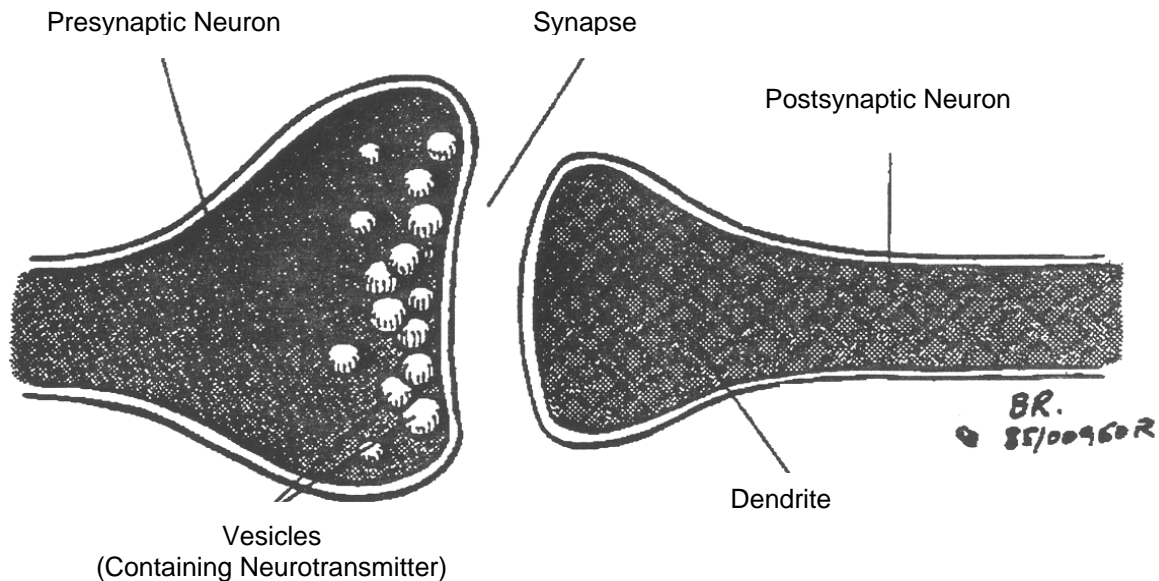
FIGURE 14: CONDUCTION OF NERVE IMPULSE



SYNAPTIC TRANSMISSION OF THE NERVE IMPULSE

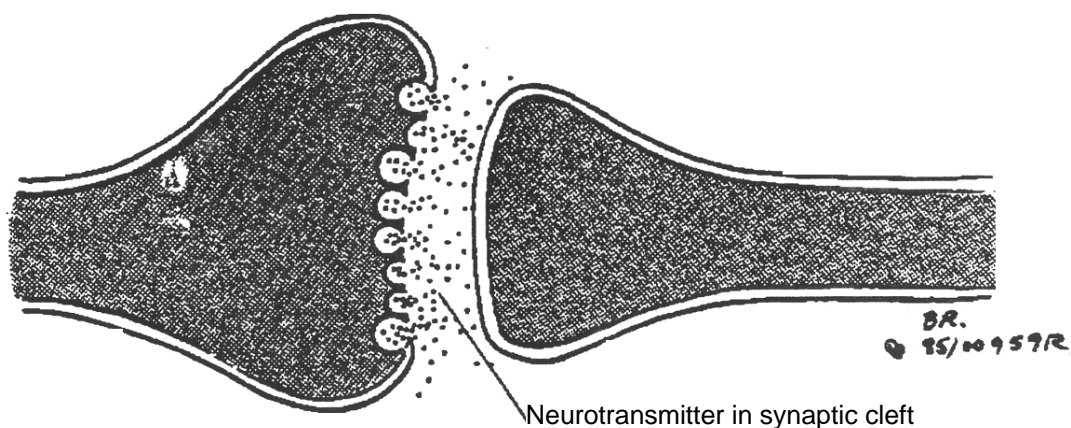
A synapse is a very small cleft, located between the end of one neuron (presynaptic neuron) and the dendrite end of the adjacent neuron (postsynaptic neuron) (Figure 15). Tiny sacs or vesicles, each containing a chemical neurotransmitter, are located in the end of the presynaptic neuron.

FIGURE 15: THE SYNAPSE

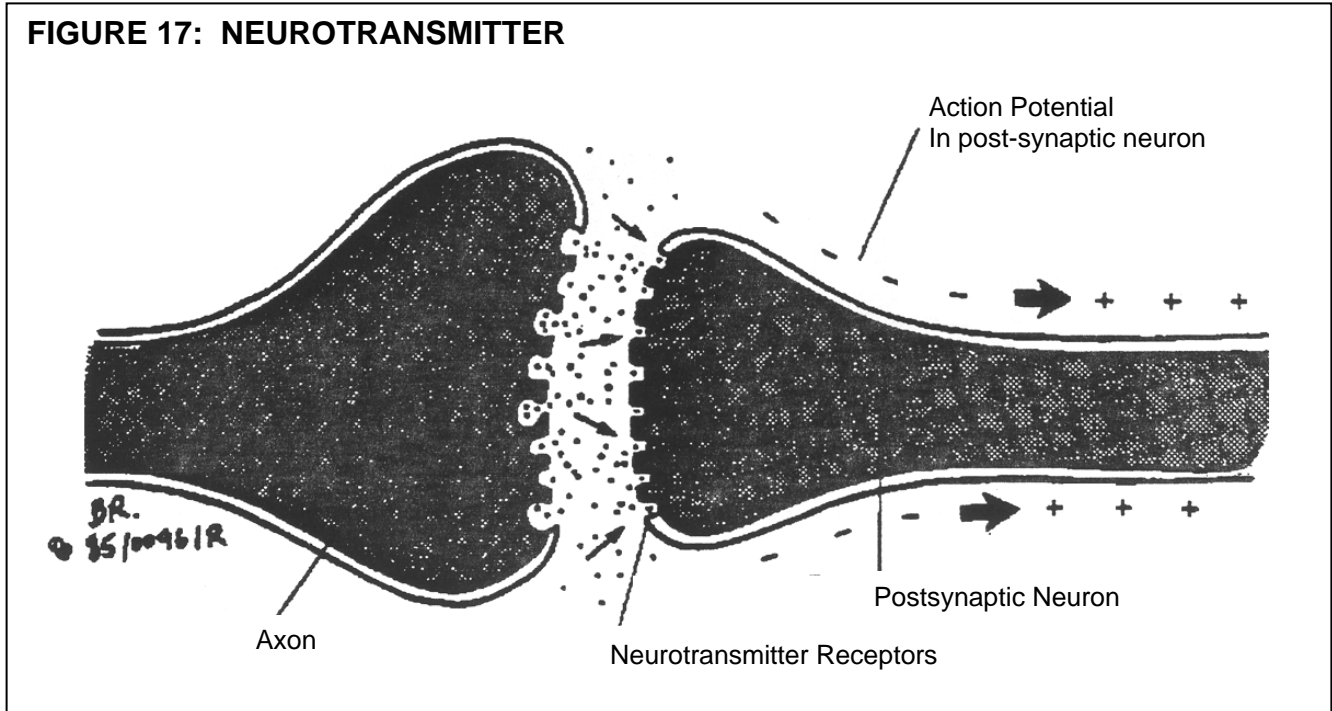


When the action potential (wave of depolarization) reaches the end of the presynaptic neuron, the vesicles move to the surface of the axon membrane. The vesicles fuse with the terminal surface and release their contents into the synaptic cleft (Figure 16).

FIGURE 16: NEUROTRANSMITTER IN SYNAPTIC CLEFT



The neurotransmitter molecules diffuse across the synapse and contact the membrane of the postsynaptic neuron (Figure 17). Here the neurotransmitter binds to specific protein sites (neurotransmitter receptors). This action facilitates the opening of channels in the membrane which increases the permeability of the membrane to sodium, **e.g.** creates a site of depolarization. This act initiates the depolarization of adjacent portions along the axon, giving rise to the nerve impulse in the postsynaptic neuron.



Knowledge of the neurotransmitter substance is important in understanding the disease processes involving them, as well as the effects of various medications upon the mechanism of impulse transmission at the synapse.

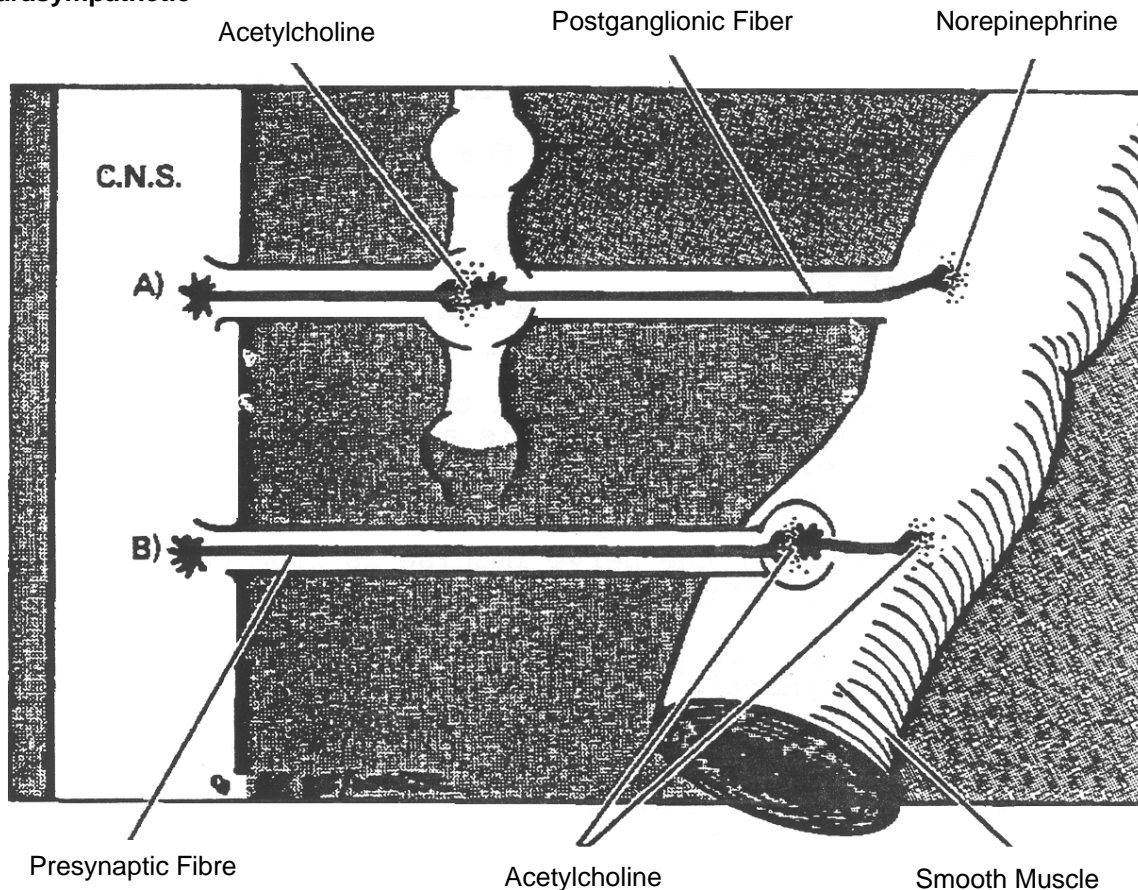
Although there are many different neurotransmitter substances, the most notable are listed below.

		Neurotransmitter
○	Somatic nervous system	Acetylcholine
○	Parasympathetic – preganglionic fibers	Acetylcholine
	– postganglionic fibers	Acetylcholine
○	Sympathetic – preganglionic fibers	Acetylcholine
	– *postganglionic fibers	Norepinephrine (Noradrenalin)

*Although within the sympathetic nervous system norepinephrine is generally the neurotransmitter communicating between the postganglionic nerve fiber and the effector organ, there are instances where acetylcholine acts the neurotransmitter communicating between the postganglionic nerve fiber and the effector organ. For instance, sweat glands and skeletal muscle blood vessels both receive postganglionic sympathetic innervation via the neurotransmitter acetylcholine.

FIGURE 18: AUTONOMIC NERVOUS SYSTEM: NEUROTRANSMITTERS

- A) Sympathetic
- B) Parasympathetic



Summary

The nerve impulse that occurs along a series of neurons is an **electrochemical** process; it is electrical along the axon membrane and chemical at the synapse. The wave of depolarization continues over succeeding neurons, until the message reaches the brain, where interpretation occurs.

**ADVANCED LIFE SUPPORT
PRECOURSE
NERVOUS SYSTEM**

SELF-ASSESSMENT: TRANSMISSION OF NERVE IMPULSES

Marks

[1] 1. What is the functional unit of nervous tissue?

[2] 2. A synapse is found between the _____ and _____.

[2] 3. When one touches an ice cube, the impulses are carried to the brain via (a) _____ neurons. The message from the brain to the fingers are carried by (b) _____ neurons.

[2] 4. For the sympathetic nervous system the chemical released by all preganglionic nerve fibers is (a) _____. The chemical released by most postganglionic nerve fibers of the sympathetic nervous system is (b) _____.

[1] 5. The direction of the nerve impulse is from the postsynaptic the the presynaptic neurons. (True or False)

[1] 6. Neurotransmitters are chemicals found at the terminal end of the presynaptic neuron. (True or False)

[3] 7. A change in the internal or external environment of a neuron is known as a (a) _____. The property of nervous tissue to respond to a change in the environment is known as (b) _____. The ability of nervous tissue to transmit nerve impulses is the property of (c) _____.

[1] 8. The nerve impulse is a wave of _____ along the axon membrane.

9. In the following statements indicate which term is most appropriate.

(polarization, depolarization or repolarization)

[1] a) A stimulus causes a reversal of the polarity of the axon membrane, creating an electropositive interior and an electronegative exterior. _____

[1] b) The restoration of the membrane potential. _____

[1] c) Due to the fact that in the resting neuron, sodium ions move to the exterior of the cell membrane, the external surface of the axon membrane is electropositive and the interior is electronegative.

[3] 10. Describe how the nerve impulse crosses the synapse.

[1] 11. Once the threshold of stimulation has been reached, a wave of depolarization (nerve impulse) spreads along the axon. This law is known as the _____.

20 TOTAL

**ADVANCED LIFE SUPPORT
PRECOURSE
NERVOUS SYSTEM**

SELF-ASSESSMENT ANSWERS: TRANSMISSION OF NERVE IMPULSES

1. Neuron
2. End of one neuron and the dendrite (or cell body) of the next neuron.
3. a) Sensory (afferent)
b) Motor (efferent)
4. a) Acetylcholine
b) Norepinephrine
5. False
6. True
7. a) Depolarization
b) Excitability
c) Conductivity
8. Depolarization
9. a) Depolarization
b) Repolarization
c) Polarization
10. The transmission of the nerve impulse across the synapse is **chemically** mediated. The chemical, known as, a neurotransmitters is deposited into the synaptic cleft in the face of a wave of receptor sites of the postsynaptic neuron. This is the stimulus for increased membrane permeability to sodium and the initiation of the nerve impulse in the postsynaptic neuron.
11. All-or-nothing law.

**ADVANCED LIFE SUPPORT
PRECOURSE
NERVOUS SYSTEM**

PATHOLOGIES OF THE NERVOUS SYSTEM

CEREBROVASCULAR DISEASES

Cerebrovascular diseases are a prevalent group of disorders related to a **lack of sufficient blood flow to brain tissues** (cerebral ischemia). Blood flow to cerebral tissues can be impaired in one of three general ways:

- Thrombosis – secondary to arteriosclerosis (70 – 80%)
- Embolism (5 – 10%)
 - thromboembolism (travelling blood clot)
 - air embolism (travelling gas bubble), **e.g.** decompression sickness
 - fat embolism (travelling piece of atherosclerotic plaque)
- Hemorrhage due to
 - hypertension (10 – 20%)
 - ruptured cerebral aneurysm (5 – 10%)
 - intracranial mass (5 – 10%)

Transient Ischemic Attacks (TIA's) are short-lived, episodic periods of cerebral ischemia that usually last 5 to 30 minutes, and may extend up to 24 hours. These attacks disappear spontaneously with no resultant neurological deficit.

TIA's may be prodromal to an actual stroke (CVA) and can present with any or all of the following:

- Numbness
- Weakness on one side of the body
- Speech difficulties
- Blurring of vision or blindness in one eye
- Dizziness
- Mental confusion
- Drop attacks, with or without loss of consciousness.



Clinical vignette

These findings are not necessarily unique to TIA's.

All of the following factors predispose people to atherosclerosis, which can lead to CVA:

- o Age
- o Hypertension
- o Smoking
- o Elevated serum lipid levels
- o Diabetes mellitus
- o Male
- o Obesity

Stroke symptoms usually appear suddenly and progress quickly. The signs and symptoms for a CVA depend on the extent of involvement of neural tissue and the side of the cerebrum that is affected. The potential for life-threatening problems may be immediate.

Some patients who have suffered a thrombotic ischemic stroke can be treated with fibrinolytic therapy. This therapy is most efficacious when the patient receives treatment within three hours of symptom onset.

SEIZURES

Seizures are periods of abnormal electrical activity in the brain (neurological dysfunction). A seizure is a symptom, not a disease and may present from an idiopathic, a metabolic, or a traumatic origin.

Grand mal seizures present with a sudden loss of consciousness, extensor muscle spasms (tonic stage), apnea and then bilateral clonic movements (generalized shaking). Once the seizure stops, the patient then passes into a postictal stage identified by muscle relaxation, deep breathing and a slowly increasing level of consciousness or sleep.

Focal seizures usually occur unilaterally and are caused by a focal brain lesion. These may present with only one body part involved or may evolve from this to include the whole body, **i.e.** a grand mal seizure.

These are the most common presentations of seizures. It is important to note that there is no such thing as a benign seizure and that uncontrolled seizures kill brain cells.

The consequences of full body convulsions may include:

- o Hypoxia
- o Acidosis
- o Cardiac arrhythmias
- o Circulatory collapse
- o Fever
- o Increased ICP.

HEAD INJURY

One of the most common traumatic insults is head injury. In the prehospital setting, it must be emphasized that all patients with head injuries from trauma must be considered to have neck or spinal injuries.

In reviewing head injury itself, lacerations, fractures, concussion, cerebral contusion and intracranial, bleeding must be considered.

Scalp lacerations must be cared for as a secondary consideration in relation to other neurological injuries of the skull, brain and spinal cord. However, these wounds should be managed quickly due to the fact that they bleed profusely and may contribute to the development of shock (especially in young children).

SKULL FRACTURES

Skull fractures may be classified as:

- **Simple** – linear crack or cracks (comminuted) in the skull surface with no displacement.
- **Depressed** – part of the skull is indented allowing possible associated complications, **e.g.** intracranial infection, CSF leakage, profuse bleeding, underlying brain contusion and/or tears in the cerebral tissue.
- **Basal (Basilar)** – involves the base of the skull, **e.g.** floor, when seen from above. (For the paramedic the classic signs of a basilar skull fracture, **e.g.** the raccoon eyes, Battle's sign are usually not apparent for several hours.)

It should be emphasized that a skull fracture does not necessarily indicate a cerebral injury and vice versa, a cerebral injury may occur without a skull fracture.

BRAIN INJURY

Concussion is a transient, limited process that usually occurs as a result of a direct blow to the head, or from an acceleration/deceleration injury, in which cerebral tissue impacts with the inside of the skull. It involves a period of unconsciousness. The brief interruption of the RAS which causes temporary unconsciousness may also cause a short period of amnesia. There is no actual damage to brain tissue.

A **contusion**, an actual bruise of the brain surface resulting in a structural alteration of the brain, is caused by the brain raking over the bony irregularities inside the skull. These patients are unconscious, at least initially. With any contusion there is actual damage to the brain of variable degree.

In either uncomplicated concussion or contusion, the patient will remain stable or improve. These injuries, as well as any direct trauma are known as **primary** injuries. **Secondary** injuries resulting from associated hemorrhage and/or edema may be life-threatening since the result is an increase

in intracranial pressure (ICP). The consequences of this condition are important for the prehospital care worker to understand.

Intracranial hemorrhage frequently results from blunt head trauma. It usually presents with a loss of consciousness (due to an interruption in the electrical activity in the brain) and with motor and/or sensory hemorrhage most often results from a cerebrovascular accident (CVA), or a ruptured cerebral aneurysm (subarachnoid hemorrhage). The hemorrhage may be **epidural, subdural, subarachnoid** or **intracerebral**.

1. An epidural (or **extradural**), **hemorrhage** is bleeding between the skull and dura mater. It is usually caused by acute head trauma from a direct blow which results in a skull fracture (50%) and a torn middle meningeal artery (temporal lobe skull fracture). Epidural hemorrhage occurs in 1-2% of patients with severe head injuries.

This injury should be suspected if there is a momentary loss of consciousness followed by a lucid interval and then a decreasing level of consciousness. In about 5% of patients this is the classic observation; usually there is no lucid interval.

2. A **subdural hemorrhage** is caused by active bleeding (usually venous) between the dura and arachnoid mater. It occurs frequently in patients with blood dyscrasias or those taking anticoagulants. Subdural venous bleeding may also be caused by head trauma, usually an acceleration/deceleration incident.

Subdural hemorrhage occurs post trauma six times more frequently than does epidural hemorrhage. This type of hematoma may occur acutely, shortly following trauma, or chronically, taking days, weeks or months to manifest symptoms.

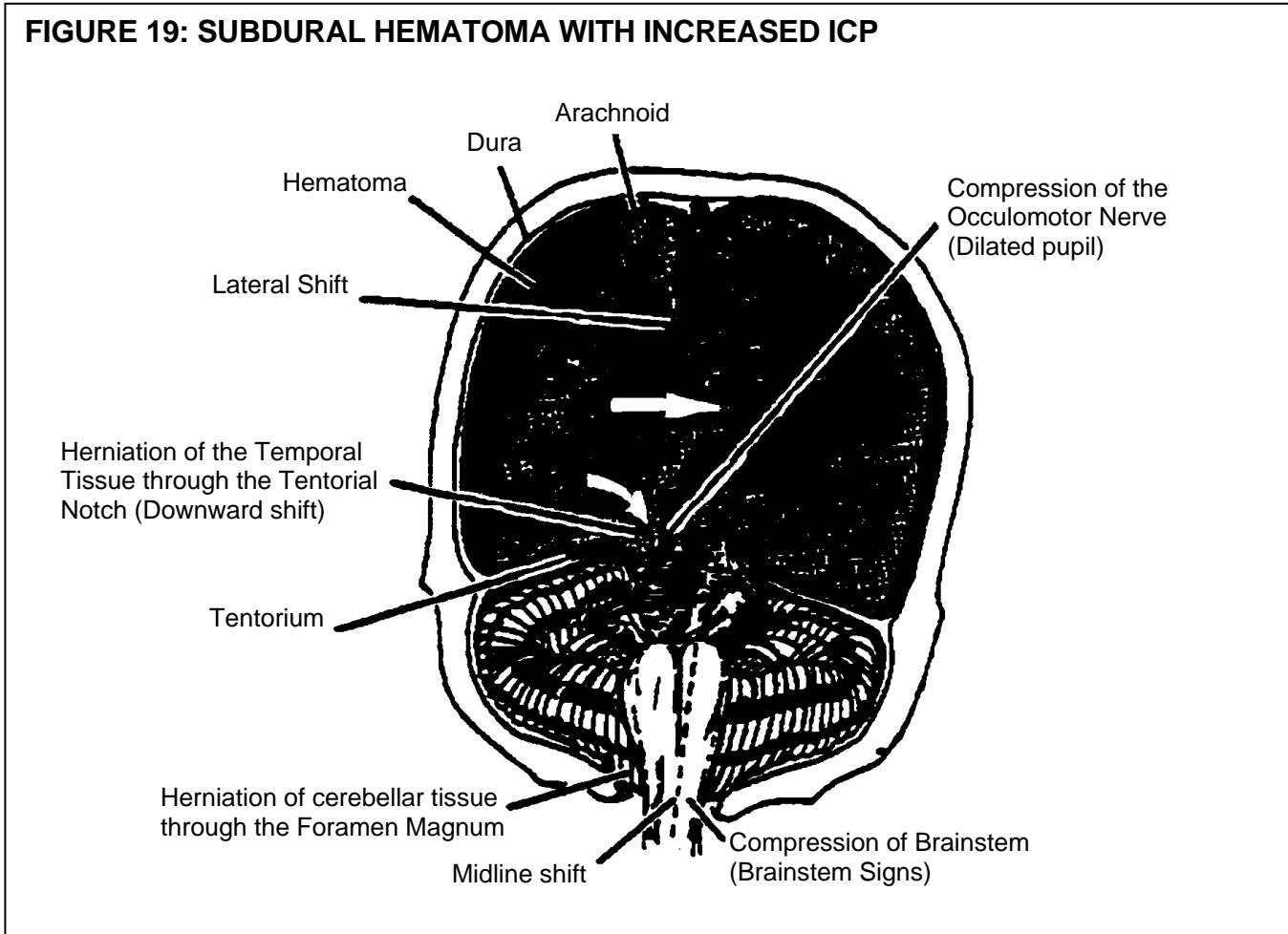
The development of a chronic subdural hematoma following trauma is especially common in the elderly and chronic alcoholics. This is due to brain shrinkage (atrophy) and the resultant stretching of blood vessels associated with these conditions. The hematoma may gradually increase in size, thus gradually creating signs and symptoms of increased ICP.

3. **Subarachnoid hemorrhage** develops from bleeding between the arachnoid and pia mater. It usually results from the rupture of a congenital intracranial aneurysm, hypertension, or head trauma. It is the most common bleed associated with head trauma.
4. **Intracranial hemorrhage** involves bleeding into cerebral tissue. It occurs in 1-2% of patients with head injury, but may also occur spontaneously.

Lesions or bleeding in the head are named according to their location in respect to the three meningeal layers of the brain or the structure involved. We have discussed that the brain is a very delicate collection of tissues cushioned by CSF and protected by the hard, bony skull which encloses the brain within a confined space. The contents of this space, **i.e.** blood, CSF and brain tissue, cannot increase in size without increasing pressure within this space.

Compensatory mechanisms with increased ICP are limited. They include a shift of CSF and decreased cerebral bloodflow. If ICP reaches a point where brain cells cannot be adequately perfused, the cells become hypoxic and soon permanent neuronal damage or death may result.

Tough dural tissue called tentoria (singular tentorium) support and compartmentalize various parts of the brain. When maximum compensation of CSF and bloodflow is reached, tissue begins to shift. Figure 19 shows three possible areas of shift – lateral, downward through the tentorial notch and downward through the foramen magnum. The resulting signs of brainstem compression are late signs.



ASSESSMENT OF BRAIN FUNCTION

The **Glasgow Coma Scale (G.C.S.)** is a widely used guide to measure changes in brain function. This scale is designed to allow the person assessing the patient to quantitatively relate the level of consciousness to the various “motor”, “verbal” and “eye opening” response of the patient as determined by a set of standardized stimuli*. The prehospital worker should assess the patient according to each section and tabulate a total score (8 or less indicates **coma**). The higher the score, the greater the degree of cerebral arousal.

The G.C.S. allows a maximum of 15 points. Testing is divided into three categories:

- o Eye opening
- o Verbal response
- o Motor response.

Eye Opening

The examiner determines the **minimum stimulus** that evokes opening of one or both eyes. If the patient cannot realistically open the system because of bandages or lid edema, write “E” after the total test score to indicate omission of this component.

- 4 points** Eyes open spontaneously.
- 3 points** Eyes open to speech. Patient opens eyes in response to command or on being called by name.
- 2 points** Eyes open to noxious stimuli.
- 1 point** No eye opening in response to noxious stimuli.

Best Verbal Response

The examiner determines the **best** response after arousal. Noxious stimuli are employed if necessary. Omit this test if the patient is dysphasic, has oral injuries, or is intubated.

- 5 points** Oriented patient. Can converse and relate who he is, where he is and the year and month.
- 4 points** Confused patient. Is not fully oriented or demonstrated confusion.
- 3 points** Verbalizes. Does not engage in sustained conversation, but uses intelligible words in an exclamation (curse) or in a disorganized manner which is nonsensical.
- 2 points** Makes moaning or groaning sounds that are not recognizable words.
- 1 point** No vocalization. Does not make any sound even in response to noxious stimulus.

Best Motor Response

The examiner determines the best response with either arm.

- 6 points** Obeys simple commands. Raises arm on request or holds up specified number of fingers. Releasing a grip (not grasping, which can be reflexive) is also an appropriate test.
- 5 points** Localizes noxious stimuli. Fails to obey commands but can move either arm toward a noxious cutaneous stimulus and eventually contacts it with the hand. The stimulus should be maximal and applied in various locations, **i.e.** sternum pressure or trapezius pinch.
- 4 points** Flexion withdrawal. Responds to noxious stimulus with arm flexion but does not localize it with the hand.
- 3 points** Abnormal flexion. Adducts shoulder, flexes and pronates arm, flexes wrist and makes a fist in response to a noxious stimulus (formerly called decorticate rigidity).
- 2 points** Abnormal extension. Adducts and internally rotates shoulder, extends forearms, flexes wrist and makes a fist in response to a noxious stimulus (formerly called decorticate rigidity).
- 1 point** No motor response. Exclude reasons for no response, **e.g.** insufficient stimulus.

REFLEXES

When we speak of subcortical activity associated with motor function, we are referring to primitive responses. Reflex arcs and nerve pathways consisting of two or three neurons, are the structural and functional units of reflex activity.

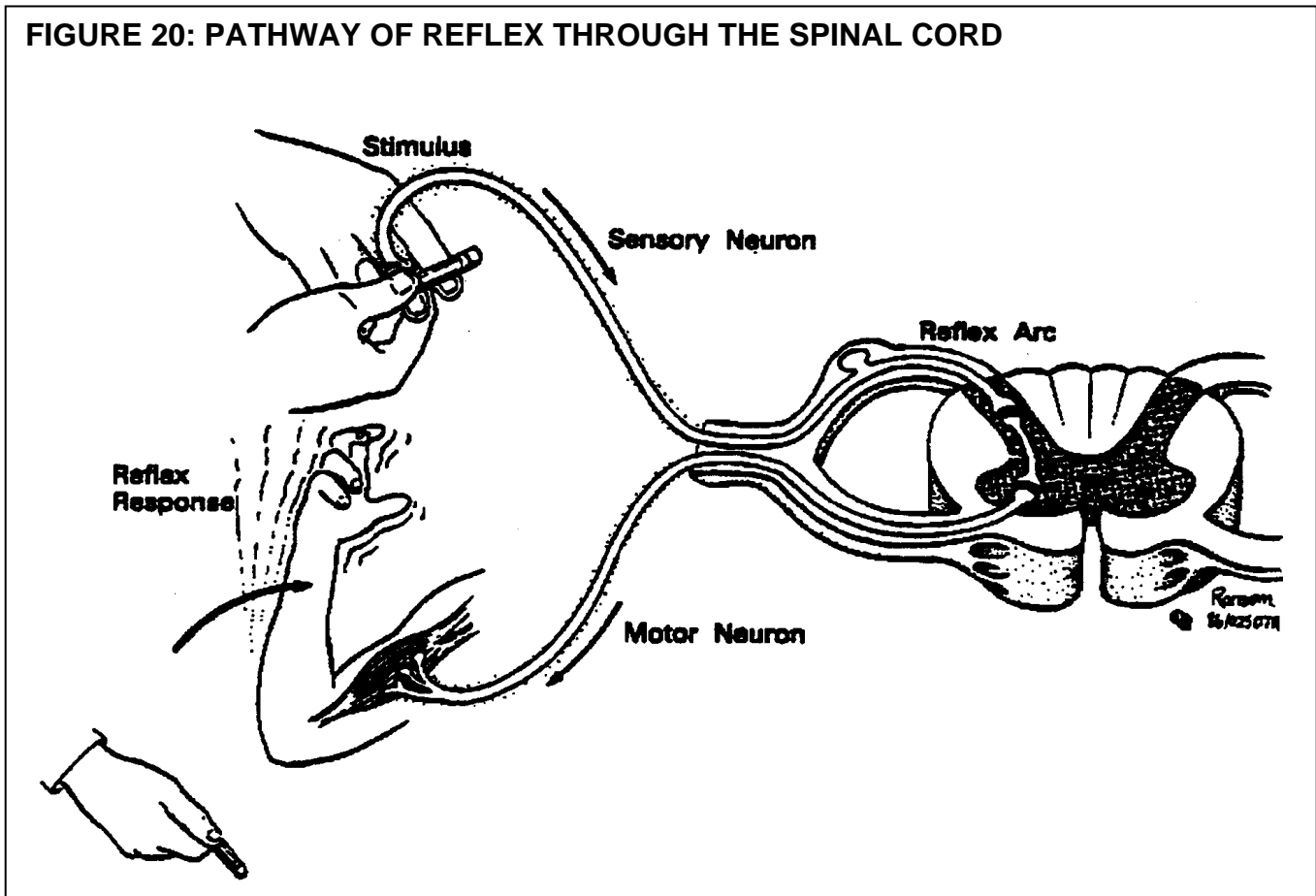
A reflex is a protective involuntary response to a stimulus. **Somatic** reflexes are contractions of skeletal muscles; while **autonomic** (or visceral) reflexes consist either of contractions of smooth or cardiac muscle, or secretion by glands.

One reflex commonly tested by prehospital personnel during insertion of an oropharyngeal airway is the gag. Its presence is protective of oropharynx in that its stimulation results in a forceful outward ejection of the irritant, sometimes accompanied by vomiting.

Another reflex you encounter frequently is pupillary response to a light stimulus. Parasympathetic fibers of the third cranial nerve (oculomotor) pass through a narrow opening in the dura (tentorial notch), which separates the cerebrum from the cerebellum. With increased ICP originating above this area, **e.g.** from any expanding lesion in the cerebrum or its meninges, third nerve compression occurs at this notch (Figure 19). The reflex response to light is lost on the same side as the compression. Bilateral pressure causes bilaterally fixed dilated pupils.

Both pupillary response and gag reflexes are **cranial** reflexes. **Spinal** reflexes tested in the field indicated whether sensory function exists and whether motor function is intact. This is best demonstrated by the application of a painful stimulus for patients not displaying voluntary motor activity.

FIGURE 20: PATHWAY OF REFLEX THROUGH THE SPINAL CORD



FACIAL TRAUMA

Facial trauma should be considered separately, when discussing head injury, since it is one of the most commonly seen types of trauma. Facial trauma is mentioned here to point out that, despite the profuse bleeding that may be present, other concurrent injuries of a more serious nature may be developing, **e.g.** airway problems, shock, spinal cord injuries and intracranial problems.

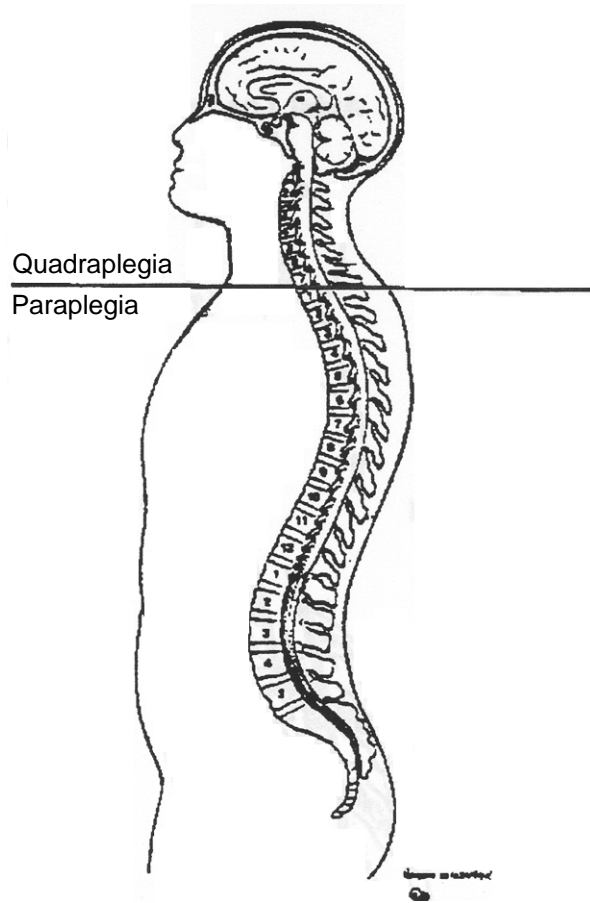
SPINAL CORD INJURY

Spinal cord injuries are common problems dealt with by the prehospital care worker. The consequences of spinal cord injury depends on the location and extent of the damage sustained and may include spinal shock, sensory losses, or motor losses; all of which may be transitory or permanent. Associated paralysis may be flaccid (accompanied by muscle atrophy) or spastic (accompanied by uncontrolled muscular spasms).

C3, C4, and C5 sections of the spinal cord contain the phrenic nerve which innervates the diaphragm. Injury to this area will result in a loss of control of the main muscle ventilation. Therefore ventilation must be supported if the patient is to survive.

It should be stressed that vertebral injuries may be present without spinal cord injury. The potential for cord injury is always present and careful handling of these patients is essential.

FIGURE 21: SPINAL CORD INJURIES



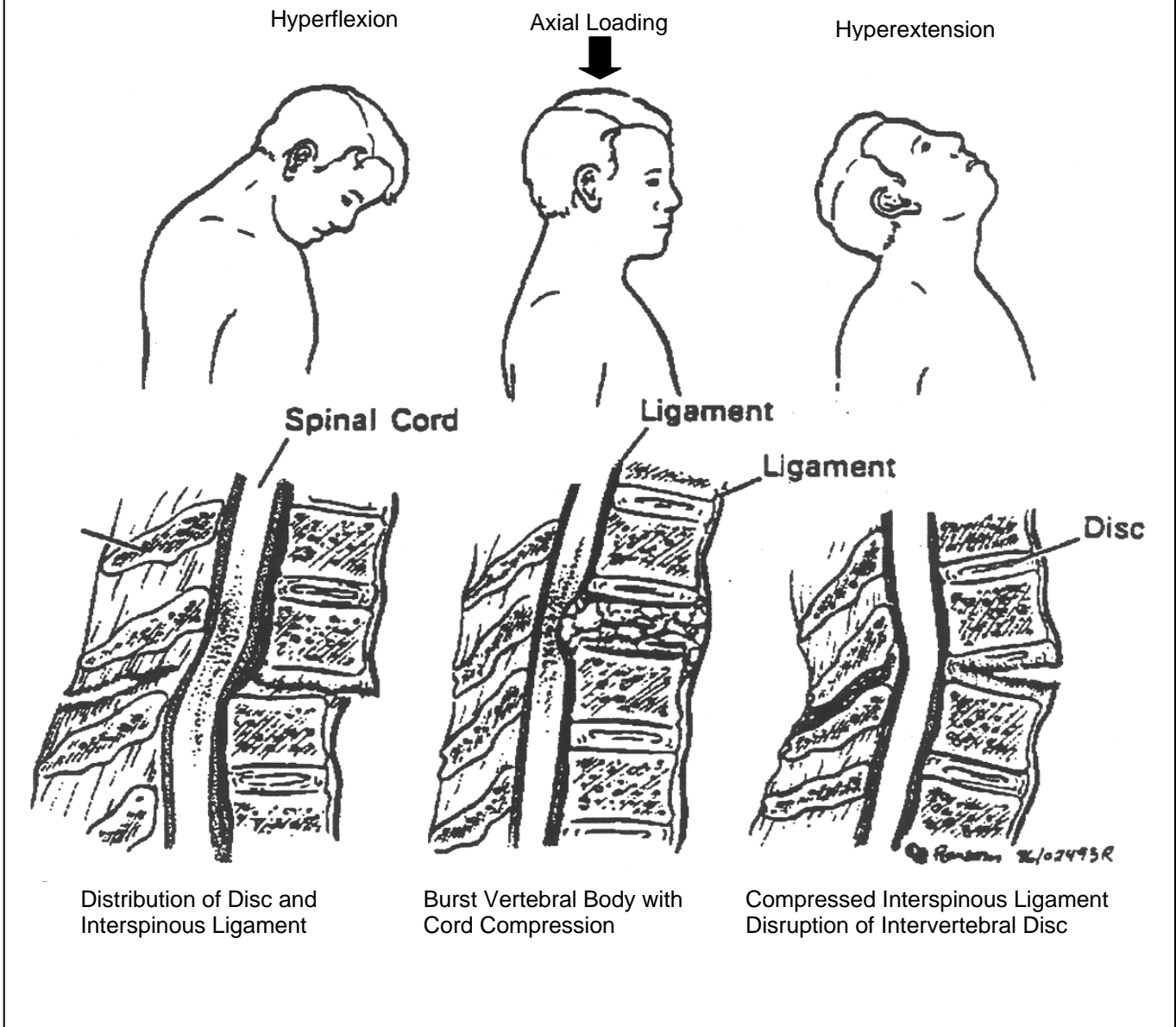
There are three basic types of spinal column injuries:

- o Wedge or compression fracture
- o Burst fracture
- o Subluxation and/or fracture/subluxation (extremely unstable).

The most common mechanisms of injury for spinal column injuries are:

- o Hyperflexion
- o Hyperextension
- o Axial loading
- o Penetrating wounds.

FIGURE 22: MECHANISMS OF SPINAL CORD INJURIES



Spinal injuries at the time of occurrence may be complete (with no neurological function) or incomplete (with some neurological function).

Cervical and lumbar spine injuries are the most common type of spinal cord injury. However, another vulnerable area is at the point where the fixed thoracic spine joins the lumbar spine. Trauma to the thoracolumbar junction (T10 to L2), from either a direct blow or from flexion-rotational forces, may produce a very unstable spinal injury. If this type of injury is suspected, the paramedic should be alerted to associated intra-abdominal or intrathoracic injuries with may well be life-threatening.

Whiplash injury, most commonly a result of a rear-end automobile accident, may produce damage to muscles, discs, ligaments, and nervous tissue in the region of the cervical spine. It is usually caused by violent hyperextension and flexion of the neck.

It must be emphasized that a cervical spine injury must be assumed in any patient presenting with:

- Injuries above the level of the clavicles
- An altered level of awareness associated with possible trauma
- Multiple severe injuries.

With this in mind, appropriate precautions should be taken when assessing and treating these patients.

**ADVANCED LIFE SUPPORT
PRECOURSE
NERVOUS SYSTEM**

SELF-ASSESSMENT: PATHOLOGIES OF THE NERVOUS SYSTEM

Marks

[1] 1. What two kinds of nerve fibers are necessary for a reflex action involving the spinal cord.

[1] 2. The three general causes of seizures include:

[1] 3. The most rapid increase in ICP will probably be due to what pathological process?

[1] 4. Which two groups of individuals are more likely to develop a chronic subdural hematoma.

[2] 5. An epidural hemorrhage is found a) _____, often secondary to
b) _____.

[4] 6. You have applied a painful stimulus to an unresponsive patient. Utilizing the GCS, list in order what specific actions (or observations) you would have performed (or noted) prior to this action.

[2] 7. What is the differences between a TIA and a CVA?

[2] 8. The two most vulnerable areas of the spinal column in the traumatized patient are:

[2] 9. Cranial reflexes tested in the field include:

[3] 10. The general causes of cerebral ischemia include:

19 TOTAL

**ADVANCED LIFE SUPPORT
PRECOURSE
THE NERVOUS SYSTEM**

SELF-ASSESSMENT ANSWERS: PATHOLOGIES OF THE NERVOUS SYSTEM

1. Sensory and motor fibers.
2. Metabolic
Traumatic
Unknown (idiopathic).
3. Arterial bleeding.
4. The elderly and the alcohol abuser.
5. a) Outside the dura, under the skull
b) Temporal skull fracture associated with middle meningeal artery tear.
6.
 1. Observed for spontaneous eye opening
 2. Observed for eye opening to speech
 3. Observed for any verbal response
 4. Observed for any motor response to verbal command.
7. Although the initial presentation may be similar, a TIA resolves spontaneously, usually within 24 hours or less with no residual neurologic deficit. The ischemia is of a transient rather than a permanent nature.
8. The cervical spine
The lumbar spine.
9. Pupillary response to light
Gag.
10. Thrombosis
Embolism
Hemorrhage.

**ADVANCED LIFE SUPPORT
PRECOURSE
NERVOUS SYSTEM**

EVALUATION

Upon completion of this module, please fill in and return this form to your base hospital co-ordinator.

Your comments will help to ensure that this unit is a useful learning module. Please indicate any problems that you may have encountered. All suggestions for improvement are welcomed.

1. How long did it take to complete this module? Please estimate.

Reading	_____	hours
Self assessment	_____	hours
Total time	_____	hours

2. Were the objectives of the module clearly stated?

yes no
If no, please comment.

3. Did you see any of the resource materials?

yes no
If yes, which items

Were they helpful? _____

4. Were the reference notes adequate?

yes no
If no, please comment.

5. Were the reference notes easy to follow?

yes no
If no, please comment.

6. Were the examples provided satisfactory?

yes no

If no, please comment.

7. Were any of the self-assessment questions poorly worded?

yes no

If yes, please specify.

8. Was the level of the module satisfactory for your program of study?

yes no

If no, please comment.

Base Hospital _____

9. General comments or suggested improvements.